



**European
Training
Curriculum**
for Sub-
specialisation
in Radiology

Curriculum for the Level III
Training Programme
(Subspecialisation beyond Year 5)

Preface	Page 5
FRAMEWORK FOR SUBSPECIALTY TRAINING IN EUROPE	Page 7
1. Duration and Structure of Training	Page 7
2. Infrastructural Aspects of the Training Programme	Page 9
3. Roles of the Subspecialty Radiologist	Page 12
4. Concept of Knowledge, Skills, Competences and Attitudes	Page 13
B-III: LEVEL III TRAINING PROGRAMME (BEYOND YEAR 5)	Page 14
B-III-1 Breast Radiology	Page 16
B-III-2 Cardiac and Vascular Radiology	Page 22
B-III-3 Chest Radiology / Thoracic Imaging	Page 28
B-III-4 Emergency Radiology	Page 35
B-III-5 Gastrointestinal and Abdominal Radiology	Page 41
B-III-6 Head and Neck Radiology	Page 52
B-III-7 Interventional Radiology / weblink included	Page 59
B-III-8 Musculoskeletal Radiology	Page 60
B-III-9 Neuroradiology	Page 66
B-III-10 Oncologic Imaging	Page 70
B-III-11 Paediatric Radiology	Page 75
B-III-12 Urogenital Radiology	Page 86
B-III-13 Medical Imaging Informatics	Page 92

Coordination: ESR Office, Am Gestade 1, 1010 Vienna, Austria
 Phone: +43 1 533 40 64-28 | Fax: +43 1 533 40 64-448
 E-mail: boardaffairs@myesr.org | www.myESR.org
 All data as per date: February 2020
 ESR accepts no responsibility for errors or misprints

Copyright notice

You may take temporary copies necessary to browse this website on screen. Universities and National Societies dedicated to the promotion of scientific and educational activities in the field of medical imaging are entitled to use the material as a guideline for educational purposes, but appropriate credit must be given to the ESR. Material must be reproduced as originally published and full credit must be given to the original publication.

This copyright notice must not be altered or removed. This material is for non-commercial use only, any commercial use of the material in whole or in part is strictly prohibited.



EUROPEAN TRAINING CURRICULUM FOR SUBSPECIALISATION IN RADIOLOGY

PREFACE TO THE EUROPEAN TRAINING CURRICULUM FOR SUBSPECIALISATION IN RADIOLOGY

The European Training Curriculum for Subspecialisation in Radiology provides curricular contents for a full subspecialisation in the field of radiology corresponding to Level III training. Level III training should be a formal, full-immersion training in a radiological subspecialty with an expected minimum of one year after the completion of radiology (Level I and Level II) training. Level I and II contents are provided in the European Training Curriculum for Radiology with Level I covering years 1 to 3 and Level II covering years 4 and 5 of training.

The European Training Curriculum for Subspecialisation in Radiology is a living document and needs to be reviewed at regular intervals in order to keep up with current developments in the profession. The societies contributing to the development of the ETC provided, where necessary, important updates to their respective chapters. Furthermore, the chapter on Medical Imaging Informatics, first introduced by the European Society of Medical Imaging Informatics (EuSoMII) in the 2018 version of the ETC, underwent a substantial revision and its content was redefined by the ESR eHealth and Informatics Subcommittee in collaboration with EuSoMII.

I would like to acknowledge the contribution of all ESR Subspecialties and Allied Sciences Member Societies, the eHealth and Informatics Subcommittee, the ESR Subspecialties and Allied Sciences Committee, the Board of Directors and the Executive Council of the European Society of Radiology as well as all the office team of the ESR for their immensely valuable support.

Rome, March 2020

Carlo Catalano
Chairperson of the ESR Education Committee
March 2018-2021



**EUROPEAN TRAINING CURRICULUM
FOR SUBSPECIALISATION IN RADIOLOGY
(LEVEL III)**

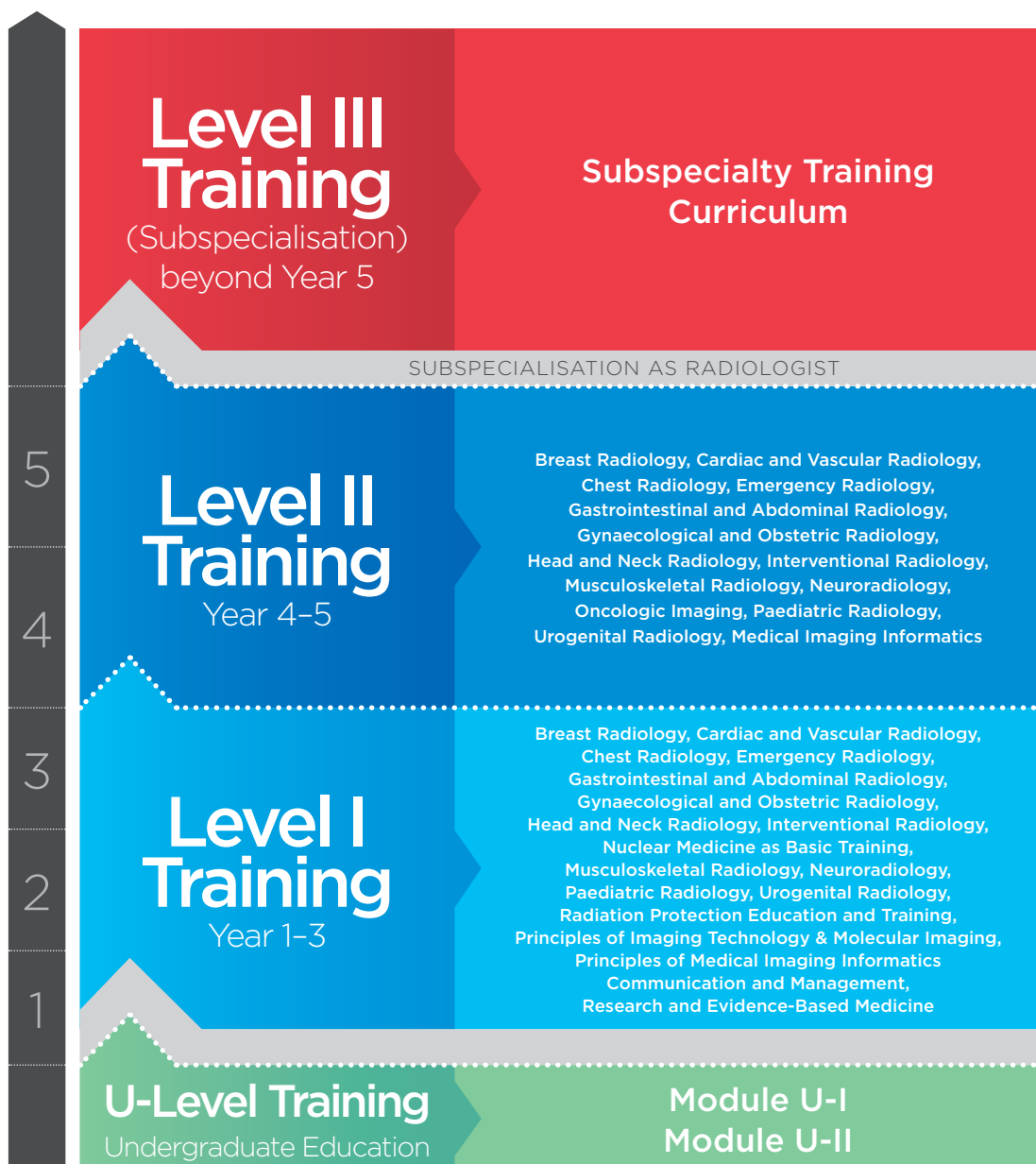FRAMEWORK FOR SUBSPECIALTY TRAINING IN EUROPE

- » A-1 Duration and Structure of Training
- » A-2 Infrastructural Aspects of the Training Programme
- » A-3 Roles of the Subspecialty Radiologist
- » A-4 Concept of Knowledge, Skills, Competences and Attitudes

FRAMEWORK FOR SUBSPECIALTY TRAINING IN EUROPE

1. DURATION AND STRUCTURE OF TRAINING

Level III Training is a formal, full-immersion training in a radiological subspecialty; a minimum of one year is expected after the completion of radiology (Level I and Level II) training. The European Training Curriculum for Radiology outlines a five-year (3 + 2) training period, consisting of Level I Training over the first three years followed by a more flexible Level II Training with potential special interest (subspecialty) rotations during the last two years.



Parts of Level II Training in a subspecialty may be counted for the subspecialisation portfolio. Depending on local facilities 50% of the training in year 4 and 5 can be devoted to subspecialty training. This will then be counted as basic subspecialty training. However, full subspecialisation always requires further Level III (subspecialty) Training beyond Level I and Level II Training.

Subspecialty training should be competency-based and may be performed in a modular fashion where subspecialty competences can be obtained over a period of time, partly within Level II, with an extra training of a minimum of one year after Level II training.

A written or electronic logbook of activity should be maintained during the whole training period, Level II subspecialty training and Level III training. This should provide a formal validated record of competences achieved and examinations performed and should form an integral part of regular assessments of satisfactory training. The time to obtain all the competences is free. Only after fulfilling all the competences a final subspecialty examination can be done.

For trainees, options to actively perform radiological research projects in the subspecialty should be promoted and become part of the competences.

The recommendations of this Subspecialty Training Curriculum are not an end in themselves, but should be interpreted in the context of understanding the seamless transition from training to lifelong continuous medical education (CME) and continuous professional development (CPD). An appreciation of this continuum should be instilled at an early stage of training already.

A programme for re-accreditation in the subspecialty - which contains time dedicated to the subspecialty and minimal CME - should be developed by the accrediting body, subspecialty society.

2. INFRASTRUCTURAL ASPECTS OF THE TRAINING PROGRAMME

TRAINING MODULES

The precise structure of the modules will vary from country to country and from department to department, but the time balance should reflect the importance to the core of practice in the subspecialisation. Every country should develop a subspecialty training programme that is realistic and achievable within the local context. When developing a training programme the general principle of this document should be followed.

Training should be under the direction and supervision of the subspecialty unit of a large radiology department. Each training programme should outline the educational goals and objectives of the programme with respect to knowledge, skills, competences and other attributes. Teaching should include didactic lectures, tutorials etc., but there should also be a large component of one-to-one apprenticeship relations with the staff faculty.

The spectrum of patient and investigative material available during training should be sufficient to enable the trainee to gain experience in all aspects of the subspecialty, including imaging-based tissue sampling and therapeutic radiology. When possible, training should ideally be integrated into a single department; however, attendees of an institution with limited specialties may be required to ensure comprehensive training elsewhere.

Within each teaching department, a local head of the subspecialty training programme with direct responsibility for in-house training should be appointed to ensure that an appropriate proportion of service versus training time be maintained. This head of subspecialty training is also responsible for the final signing of the logbook, which marks the end of the training period in a subspecialty.

Regular assessments should be carried out and easy access for trainees to local coordinators should be encouraged.

The fully trained subspecialty radiologist should be capable of working independently when solving most clinical problems and those undertaking interventional procedures should also have sufficient clinical background knowledge to accept direct referrals and to clinically manage patients in the immediate time frame surrounding such interventions.

TEACHING STAFF

The number of qualified subspecialty radiologists with teaching functions in the department should be sufficient to fulfil all the needs of teaching in the subspecialty with a minimum of two accredited subspecialty staff members. If necessary, departmental support should be given for modular training outside the base hospital. The teachers should ideally attend teacher-targeted training courses and should be fully integrated into the overall university educational process. Where examinations are a feature of training, all teachers should experience the appropriate practical examinations and participate as examiners.

EQUIPMENT

Only departments with adequate imaging equipment and services should be approved for training. The equipment should comply with radiological safety standards and should be in good technical condition. Technical efficiency, security, radiation safety and controls should be of an adequate standard and conform to agreed national quality control criteria. Radiation protection should be organised and radiation should be monitored according to European standards. The techniques for adequate radiological subspecialty training will depend on local availability, but should include the following:

READING FACILITIES AND TEACHING MATERIALS

An adequate supply of teaching materials should include textbooks and journals relevant for the subspecialty area (either in print edition or in an online version). Teaching facilities should include access to online medical publications and teaching aids. A wide range of e-learning facilities have now been developed within ESR and within some subspecialty societies, and are available on the website.

COURSE PARTICIPATION AND RESEARCH

Attendance at outside courses and scientific congresses will depend on the stage of training, the local training programme and the relevance of the courses to the trainee's stage of training. Participation should be logged and recorded. A spirit of academic excellence should be fostered within the department, including a pride in profiling the department's achievement at local, national and international scientific gatherings, and in presenting scientific results in renowned, peer-reviewed national and international journals. Authorship of research publications and peer-reviewed journals should be encouraged and ongoing mentoring in this area should be made available by more senior academic staff.

TRAINEE ASSESSMENT

Formal trainee appraisal and assessment should take place at regular intervals. In order to verify that appropriate modular training has been obtained, this assessment should include appraisal of the

logbook referred to above. Competence assessments should also cover clinical and technical competences, including interpersonal skills and suitability as a clinically active doctor and the ability to work in a team.

Important Level III competences are related to the focus of a subspecialised radiologist as being a consultant for the clinician. Part of the training might therefore be a clinical working experience.

As part of the assessment process, trainees should be given an opportunity to provide their own observations on training facilities and teaching personnel on a confidential basis.

ACCREDITATION OF TRAINING DEPARTMENTS

Accreditation of training departments by a competent and independent authority coordinated through either the national society or a national authority with responsibility for training is encouraged. Subspecialty training should only be done in nationally accredited subspecialty training centres. Accreditation should be based on the principle outlined in this document.

The European Training Assessment Programme 2.0 provides assessment and certification of radiology training programmes and departments. It is a joint project of the European Board of Radiology (EBR) and the UEMS Radiology Section and is available to all institutions from countries of the ESR Institutional and Associate Institutional Member Societies. ETAP provides a high quality and objective assessment, and the subsequent certification based on the assessment results: Silver, Gold or Platinum.

KNOWLEDGE ASSESSMENT

On completion of the training period the radiologist is expected to be capable of working independently and unsupervised in a hospital or outpatient facility.

At the end of training, objective measurement of an achieved standard should be made depending on national custom and practice.

A subspecialty exam should preferably be part of the completion of training.

EUROPEAN SCHOOL OF RADIOLOGY

The European School of Radiology (ESOR) offers complementary and continuing education to young radiologists through visiting schools, visiting seminars, scholarships, fellowships and tutorials, thus enhancing and ensuring the further development of young radiologists during their training, also in the realm of subspecialty training. Also some subspecialty societies offer dedicated training modules.

The ESR Education Committee encourages young radiologists to participate in the programmes and to benefit from internationally renowned faculties and/or training in pre-selected, highly esteemed reference training centres in Europe and beyond (see <http://www.esor.org>).

3. ROLES OF THE SUBSPECIALTY RADIOLOGIST

In the 1990s the Royal College of Physicians and Surgeons of Canada began to develop the “Canadian Medical Education Directives for Specialists” to identify the roles and competences of physicians in order to improve patient care. These so-called “CanMEDS” have been applied to numerous medical education endeavours, both on the level of medical school and of residency and fellowship training and have been widely acclaimed.

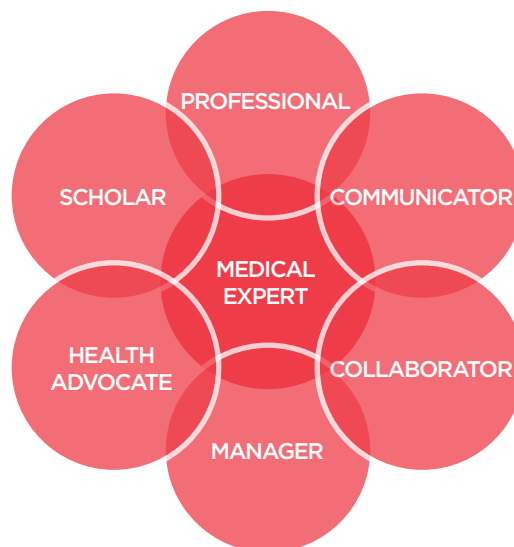
The CanMEDS framework identifies the following seven central physician roles:

1. Medical Expert
2. Communicator
3. Collaborator
4. Manager
5. Health Advocate
6. Scholar
7. Professional

The competences of physicians are centred around these seven key roles.

In order to best serve their patients, subspecialty radiologists need to gather competences in all seven areas. It does not suffice to teach trainees to gather extensive knowledge to become a subspecialty expert. It will rather be necessary to train and educate them as communicators, collaborators, managers, health advocates, scholars and professionals as well. If subspecialty radiologists are not sufficiently trained in all of these areas and roles, their crucial role in patient care will be endangered.

For subspecialty training, items 1, 2, 3 and 7 are considered the most important. Major aims of Level III training are to become a medical expert and a professional in the subspecialty field.

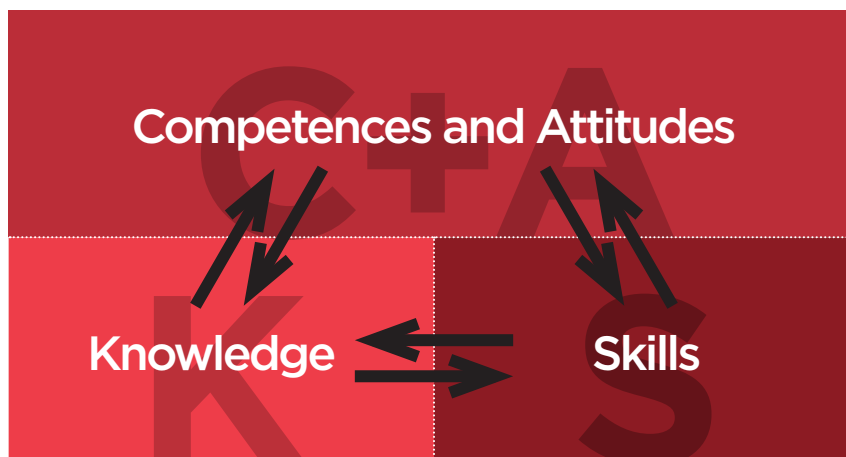


4. CONCEPT OF KNOWLEDGE, SKILLS, COMPETENCES AND ATTITUDES

In international higher and post-graduate education there has been an increasing focus on competences, rather than just education inputs. Instead of just focussing on the “learning inputs”, the “learning outputs” have increasingly been in the centre of educational attention and endeavours. This led to concepts of Knowledge, Skills and Competences (KSCs) or of Knowledge, Skills and Attitudes (KSAs). These learning outcomes are less dependent on the times and routes of acquisition.

In the European Union, the KSC concept has been used to facilitate comparability of qualifications and labour mobility across the borders of the various member states.

While the concept of “knowledge” has been the traditional basis for educational curricula providing lists of topics the trainee is expected to learn, the concepts of skills, competences and attitudes are more difficult to appreciate. The word “skill” is usually applied to describe a level of performing a particular task – this can be a motor task (e.g. performing an arterial puncture) or a cognitive task. The term “competences” has been subject to frequent debates in the past few years with several different models being in use. In the revised version of the European Training Curriculum for Radiology we introduce a category of “Competences and Attitudes”. Competences tend to develop from an initially rule-based, inflexible behaviour to an intuitive understanding and comprehension of the crucial aspects of a situation. This development should be encouraged throughout the training.



B-III:
**LEVEL III
TRAINING
(BEYOND YEAR 5)**

LEVEL III TRAINING (BEYOND YEAR 5)

The subject content of the curriculum for Level III Training includes the following elements:

B-III-1 Breast Radiology

B-III-2 Cardiac and Vascular Radiology

B-III-3 Chest Radiology

B-III-4 Emergency Radiology

B-III-5 Gastrointestinal and Abdominal Radiology

B-III-6 Head and Neck Radiology

B-III-7 Interventional Radiology / weblink included

B-III-8 Musculoskeletal Radiology

B-III-9 Neuroradiology

B-III-10 Oncologic Imaging

B-III-11 Paediatric Radiology

B-III-12 Urogenital Radiology

B-III-13 Medical Imaging Informatics

B-III-1 BREAST RADIOLOGY

Content provided by EUSOBI (European Society of Breast Imaging)

KNOWLEDGE

- To have detailed knowledge of the embryology, anatomy and physiology of the breast, axilla and associated structures in relation with age, hormonal status, pregnancy and lactation
- To have in-depth knowledge of common and uncommon benign breast diseases and of how these diseases manifest, both clinically and on imaging, including congenital breast abnormalities in females and males and inflammatory breast diseases
- To understand therapy protocols for inflammatory breast diseases
- To have detailed knowledge of borderline or so-called high-risk breast lesions (those defined to imply an uncertain potential for malignancy) and of their clinical and imaging features, including associated current and prospective risk of ductal carcinoma in situ (DCIS) or invasive breast cancer
- To have in-depth knowledge of common and uncommon malignant diseases of the breast, axilla and associated structures and of their clinical and imaging features, including DCIS, invasive breast cancers and inflammatory breast cancer as well as non-epithelial breast malignancies to the breast (e.g. primary breast sarcomas and lymphomas) and breast metastases originating from non-breast malignancies
- To know the clinical and imaging presentation of patients with primary occult breast carcinoma and how to search for the primary lesion and to manage these patients
- To have detailed knowledge of genetic subtypes, pathologic prognostic factors and TNM staging of breast cancer
- To have detailed knowledge of cytological and pathological reporting of breast diseases according to standardised classifications
- To understand the biomolecular classification of breast cancers and its imaging and therapeutic implications
- To understand the physical principles, techniques, indications and limitations of film-screen mammography and related techniques (in case this technique is still operated)
- To have detailed knowledge of physical principles, techniques, limitations and indications of digital mammography (DM), including standard and additional projections, ductogalactography (in case this technique is operated), mammographic stereotactic guidance for needle sampling and presurgical localisation, digital breast tomosynthesis (DBT), reconstructions of 2-dimensional mammograms from DBT datasets (if these type of images are available) and contrast-enhanced mammography (if this option is available)
- To have in-depth knowledge of physical principles, techniques, indications and limitations of ultrasound (US) of breast and axilla, including methods for US guidance for needle sampling and presurgical localisation, colour and power Doppler and elastosonography
- To have detailed knowledge of methods for US evaluation of ipsilateral axilla in patients with a newly diagnosed breast cancer and for US-guided needle sampling of suspicious lymph nodes
- To know US methods for exploring lymph nodes of the internal mammary chain in the case of newly diagnosed breast cancers, especially those located in the internal quadrants

- To know principles, techniques and advantages and disadvantages of automated breast US
- To have in-depth knowledge of physical principles, techniques, indications and limitations of breast magnetic resonance imaging (MRI), including T2-weighted imaging, high-spatial resolution dynamic contrast-enhanced T1-weighted imaging, diffusion-weighted imaging (DWI) and methods for MR guidance for needle sampling and presurgical localisation
- To be aware of methods, advantages and disadvantages of MR spectroscopy of the breast (if technique is available)
- To have detailed knowledge of general indications and contraindications to MRI and Gadolinium-based contrast materials and of differences among them in terms of safety and performance
- To be aware of the non-negligible probability of incidental extramammary findings on breast MRI
- To be aware of potential advantages and disadvantages of systems for computer assisted detection / diagnosis (CAD), applied to mammography and breast MRI
- To know principles, technique, indications and limitations of nuclide-based techniques dedicated to breast imaging: breast-specific gamma imaging (BSGI) and positron emission mammography (PEM) (if technique is available)
- To have in-depth knowledge of the clinical meaning of nipple discharge, distinguishing between benign and suspicious discharge characteristics as well as defining indications for mammography, US, ductogalactography or MRI in patients with nipple discharge
- To know the main types of breast implants used for aesthetic purposes or oncoplastic reconstruction and the clinical and imaging presentation of normal implants as well as of intra- and extra-capsular ruptures or diseases associated to the presence of implants
- To have detailed knowledge of dedicated sequence protocols for studying breast implants with MRI, including those which allow for silicone suppression, water suppression or selective excitation, fat suppression
- To have in-depth knowledge of methods for radiologic-pathologic correlation of breast lesions
- To understand epidemiological data regarding breast cancer, including incidence, prevalence and survival, with details regarding the country where breast imaging subspecialty is or will be practiced by the trainee
- To know the role of risk factors for breast cancer regarding personal history, such as age at menarche, parity, body mass index, breast density, previous biopsies, diagnosis of high-risk lesions and previous thoracic radiation therapy
- To have detailed knowledge of the role of breast density in determining a masking effect for screening mammography, significantly reducing the sensitivity of the test
- To have detailed knowledge of the role of breast density in determining a masking effect of malignant lesions, significantly reducing the sensitivity of mammography
- To have in-depth knowledge about genetic / hereditary predisposition for breast cancer, including phenotype of families with BRCA1 and BRCA2 deleterious mutations, and the role of other gene mutations in determining a higher breast cancer risk
- To know the indications for genetic counselling for suspected high-risk patients for breast cancer and the problems associated with genetic testing, including psychological issues and how to manage inconclusive results (i.e. negative BRCA1/2 testing) in high-risk families

- To have detailed knowledge of clinical management and radiological evaluation of patients presenting with a palpable breast mass, mastalgia / mastodynia, breast trauma, inflammatory findings, nipple abnormalities, skin retraction and axillary adenopathy
- To have in-depth knowledge of principles, objectives and limitations of population-based screening mammography, including lead time and length bias, difference between results for invited women and attending women, screening effect on disease-related mortality and quality-adjusted life years, differences in effect of screening according to age
- To have detailed knowledge of European guidelines for breast cancer screening and diagnosis
- To know details of screening audit in terms of desirable goals for time to diagnosis or to treatment, recall rate and positive predictive value, percentage of stage 0 (DCIS) and stage I tumours, minimal carcinomas, nodal positivity, prevalent and incident cancer rate, absolute and proportional interval cancers rate, and screen-detected stage II tumour rate, taking into account country-specific recommendations
- To know the procedure for multi-reader blinded review of interval cancers, including the subdivision into interval cancers, minimal signs and missed cancers
- To know details of structure and methods of at least one local population-based screening programme, including methods for double reading with and without arbitration
- To know the epidemiological theory of overdiagnosis, as applied to DCIS and invasive breast cancers
- To be aware of the current debate on limitations of screening programmes, including interval cancers, false positive rate and overdiagnosis of DCIS and invasive cancers
- To know the current debate on overtreatment of breast cancer and the relation between overdiagnosis and overtreatment
- To have detailed knowledge of technique, indications and limitations of image-guided methods for needle sampling of breast tissue, including fine needle aspiration (FNA), core biopsy (CB), vacuum-assisted biopsy (VAB) and radiofrequency-based excision / biopsy systems, under any type of imaging guidance
- To have detailed knowledge of indications, advantages and disadvantages of image-guided techniques for presurgical localisation, under any type of imaging guidance
- To have an in-depth understanding of the radiological methods for evaluating tumour extent and searching for additional ipsilateral malignant lesions or contralateral malignant lesions, including potential advantages and disadvantages of preoperative MRI
- To know indications and methods for neoadjuvant chemotherapy, hormonal therapy and biological targeted therapy of breast cancer and the clinical relevance of early (during treatment) and final (after treatment) imaging evaluation of tumour response
- To know principles, indications and technical variants of breast-conserving surgery, in detail for what is relevant to breast imaging
- To know principles, indications, technical variants and limitations of sentinel node biopsy
- To know principles, indications and technical variants of curative and prophylactic mastectomy, including skin- and nipple-sparing mastectomy, in detail for what is relevant to breast imaging and recurrence of breast cancer
- To know indications and methods for adjuvant chemotherapy, hormonal therapy and biological targeted therapy of breast cancer, in regard to what is relevant to breast imaging

- To know indications and methods for radiation therapy options, including whole and partial breast irradiation, in details for what is relevant to breast imaging
- To have detailed knowledge of the effects of hormone replacement therapy, surgery (including breast reduction / augmentation as well as oncoplastic reconstruction), chemotherapy, hormonal therapy and different options for radiation therapy on both clinical status and breast imaging methods (mammography, US or MRI)
- To know clinical, pathologic and imaging criteria for selecting patients for partial breast irradiation
- To have detailed knowledge of advantages, limitations and pitfalls of imaging techniques in detecting local recurrence of breast cancer
- To have an in-depth understanding of imaging methods for extramammary staging of breast cancer and evaluation of distant metastases
- To have a detailed knowledge of methods of standardised evaluation of the imaging-based oncologic status of breast cancer patients according to RECIST 1.1 criteria
- To be aware of minimally invasive therapy options for breast cancer and distant metastases
- To have detailed knowledge of clinical presentation and imaging findings of benign and malignant breast diseases in children, adolescents and pregnant and lactating women
- To have detailed knowledge of clinical presentation and imaging findings of benign and malignant diseases of the male breast, including gynaecomastia, pseudogynaecomastia and breast cancer
- To have a detailed knowledge and understanding of standardised lexicon / descriptors and diagnostic categories of breast imaging reporting with reference to lesion, breast or patient (ACR BI-RADS® or other standardised classification methods)
- To know indications and limitations of therapeutic imaging-guided techniques (radiofrequency ablation, cryoablation, electroporation, focused US, etc.) of breast cancer or benign breast diseases
- To have detailed knowledge of international recommendations for the composition of the multidisciplinary team in planning investigations, treatment and in outcome review for breast cancer patients, in particular those issued by the European Parliament
- To have an in-depth understanding of the communication principles of breaking news and the psychosocial consequences of doing so improperly
- To have detailed knowledge of legal liability in breast imaging, for both screening and clinical activity
- To know principles of evidence-based medicine applied to breast care and imaging, including the type of evidence derivable from primary studies with different designs and from systematic reviews and meta-analyses
- To know the absolute and relative costs of the various imaging examinations utilised in the management of breast diseases and to be aware of principles of cost-effectiveness analysis

SKILLS

- To take a detailed familial and personal history of women / patients in regard to disorders of the breast and risk factors for breast cancer
- To use software for estimating individual risk of breast cancer (e.g. <http://www.ems-trials.org/riskevaluator/>)
- To perform physical examinations of the breast, axilla and associated structures
- To prepare smears (or to use alternative methods) for cytological examination of nipple discharge
- To perform areolar tissue sampling in the case of suspected Paget disease (if this is usually performed by radiologists)
- To perform standard 2-view mammography respecting all quality items
- To perform 2-view mammography in women who underwent breast augmentation (Eklund projections)
- To perform additional / special mammographic views in relation to symptoms or signs
- To supervise the imaging quality of mammograms performed by technologists and to demonstrate how to obtain good views also in difficult situations
- To perform ductogalactography (if this examination is operated)
- To perform US examination of the breast and axilla, also in correlation with mammographic or MRI findings (targeted US)
- To guide the technician in performing breast MRI, suggesting the optimal sequence protocol and technical parameters
- To perform post-processing of breast MRI examinations, including temporal subtraction of dynamic contrast-enhanced studies, region-of-interest-based dynamic analysis and calculation of apparent diffusion coefficient from DWI acquisitions
- To be able to choose the best biopsy system and the best technique for biopsy guidance, taking into account patient comfort and cost-effectiveness principles
- To perform FNA, CB or VAB of breast lesions under mammographic, US and MRI guidance
- To perform FNA or CB of lymph nodes suspected as metastatic or also primary malignant
- To perform presurgical localisation under any type of image guidance
- To perform or supervise the radiography of surgical specimens and communicate with the surgeon accordingly
- To correctly interpret a perioperative radiograph of a surgical specimen
- To perform post-operatively radiologic-pathologic correlation directly interacting with the breast pathologist in difficult cases (e.g. multifocal / multicentric cancers, extensive DCIS or DCIS component)
- To recognise breast lesions also in cross-sectional images usually not used in breast imaging (e.g., computed tomography and whole-body positron emission tomography)
- To participate in double reading of screening mammography obtaining levels of sensitivity and specificity compatible with regulations of local screening programmes
- To perform abscess management, clinically and by means of image-guided procedures
- To communicate to patients the results of imaging studies and of tissue sampling, also explaining the level of uncertainty of particular cases (e.g. high-risk lesions)
- To perform and present research-related work related to scientific questions and/or evidence-based improvement and quality work in the field of breast radiology

- To critically review the literature and research articles in the field
- To conduct a research study and to evaluate and present the results in a scientific manner
- To understand the potential impact of technological development and learn how to translate results of research into clinical practice

COMPETENCES AND ATTITUDES

- To establish a high level of human interaction with the woman / patient at any step of the diagnostic process, using a lay language but keeping at the same time a professional habit
- To be able to communicate with patient's relatives in order to explain the patient's status and the perspective of further diagnostic steps or treatment; to be particularly trained in communicating breaking bad news
- To ask the patient for written informed consent prior to interventional procedures of the breast, after having explained in detail the procedure and the related risks, advantages and limitations
- To choose the best-suited method for evaluating disorders of the breast for common and uncommon clinical indications
- To be able to justify and optimise all relevant diagnostic imaging examinations and/or interventional procedures of the breast, including minimisation of X-ray exposure in mammography and choice of optimal imaging parameters for mammography, ultrasound and MRI of the breast
- To confidently judge the quality of the imaging examinations in breast imaging and to devise strategies to improve image quality in a department of breast imaging
- To teach technical staff to ensure that appropriate images of the breast are obtained
- To be able to interpret and report mammograms, breast US and MRI examinations using a clear and synthetic free text using standardised descriptors such as those defined by the ACR BI-RADS®
- To use standardised diagnostic categories with defined operational indications such as those of the BI-RADS®
- To be able to appreciate difficult cases in which it is appropriate to obtain a second opinion for interpreting and reporting clinical and imaging breast cases
- To identify urgent and/or unexpected findings in all types of imaging examinations of the breast and to communicate these timely and properly to patients and colleagues involved in the case
- To actively and positively interact with the other radiologists dedicated to breast imaging
- To appreciate and respect the roles and responsibilities of other non-medical members of the breast imaging team, e.g. clerical officers, radiographers, nurses, support staff, secretaries etc.
- To actively and positively interact with the other medical and non-medical members of the multidisciplinary breast care team, being an integral part of the team in planning investigations, treatment and in outcome review
- To attend multidisciplinary conferences and tumour boards for diseases of the breast, in the role of the radiologist responsible for the diagnostic process of the cases in discussion
- To understand the potential impact of technological development and new results of research on breast imaging practice
- To attend on a regular basis courses and meetings for a continuing professional development in breast care
- To keep up to date with changes of breast imaging practice as a consequence of a lifelong learning process
- To be prepared to support clinical trials in breast imaging and clinical trials which require breast imaging support

B-III-2 CARDIAC AND VASCULAR RADIOLOGY

Content provided by ESCR (European Society of Cardiovascular Radiology)

KNOWLEDGE

ANATOMY & NORMAL VARIANTS

- To have an in-depth knowledge of cardiovascular anatomy on CT and MRI
- To describe coronary anatomy according to the AHA classification
- To become familiar with most common anatomical variants and anomalies in coronary anatomy
- To distinguish malignant from benign coronary variants
- To describe vascular territories according to the AHA classification
- To understand the angiosome approach for peripheral arterial disease

CONGENITAL

- To understand relevant embryological principles of the heart and the great vessels
- To describe imaging and clinical features of congenital heart disease including neonatal heart disease, congenital heart disease in childhood and grown-up congenital heart disease
- To know imaging presentation and typical complications of surgical and non-surgical standard procedures in congenital heart disease

IMAGE ACQUISITION AND POST-PROCESSING

- To justify cardiac CT and MRI
- To have an in-depth knowledge of indications, contraindications, limitations and potential hazards of different cardiac and vascular imaging methods including ultrasound, computed tomography, magnetic resonance tomography, SPECT, PET, hybrid imaging and invasive angiography
- To describe diagnostic algorithms and the role of alternative diagnostic tools, such as serum biomarkers, SPECT, PET and hybrid imaging
- To describe principles, application, contraindications and limitations of contrast agents, betablockers and vasodilators in cardiac CT for the work-up of patients suffering from cardiac and vascular diseases
- To describe principles, applications and limitations of nuclear cardiac imaging
- To describe principles, applications, contraindications and limitations of cardiac pharmacologic stress testing and ergometry
- To be aware of potential life-threatening emergencies in patients suffering from cardiovascular disease referred for cardiac imaging
- To describe, teach and train standard emergency procedures in case of adverse events during or after cardiac or vascular tests

- To describe how to optimise image quality and reduce radiation exposure in cardiac and vascular CT examinations
- To describe principles of cardiac CT acquisition and modifications related to patient heart rate and BMI
- To describe principles, application, contraindications and limitations of contrast agents in cardiac and vascular applications
- To describe how to optimise image quality in cardiac and vascular MR examinations
- To understand axial, multiplanar reconstructions (MPR), maximum intensity projection (MIP) and volume rendering principles as they apply to cardiac CT and MRI
- To describe principles, techniques, pitfalls, limitations, clinical implications and relevance of coronary calcium scoring
- To describe principles, applications and limitations of nuclear and hybrid cardiac imaging
- To have a basic knowledge in the interpretation and reporting of cardiac catheter examinations, echocardiography and SPECT and PET as well as hybrid cardiac imaging
- To describe contrast bolus timing as it pertains to cardiac CT and MRI
- To describe relative costs of the various imaging examinations in cardiac imaging

CORONARY ARTERY DISEASE

- To describe diagnostic and therapeutic strategies and algorithms in coronary artery disease
- To describe principles and practice of screening techniques and risk factors in cardiac disease
- To understand pathophysiology of acquired cardiovascular disease
- To describe imaging and clinical features of coronary artery disease, including acute coronary syndrome, myocardial ischaemia, myocardial infarction, post myocardial infarction syndromes and ventricular aneurysms
- To understand the role of CT, MRI and nuclear medicine as well as hybrid examinations in the assessment of myocardial viability
- To describe manifestations of cardiovascular disease as demonstrated by conventional radiography CT, MRI, angiography, nuclear medicine and hybrid investigations and ultrasound
- To describe imaging presentations of atherosclerosis and coronary calcification on coronary CTA
- To describe unusual causes and presentations of coronary artery disease including vasculitis, hibernating and stunned myocardium
- To describe differential diagnoses relevant to clinical syndromes and imaging features of cardiovascular disease
- To know the epidemiology and classification of heart failure; to understand the role of imaging in the diagnosis of systolic and diastolic heart failure
- To be aware of the diagnostic value of cardiac imaging before cardiac transplant and resynchronisation therapy

MYOCARDIUM, PERI- AND ENDOCARDIUM, HEART VALVES, PULMONARY ARTERIES

- To know about the role of nuclear medicine and hybrid imaging techniques in endocarditis
- To describe imaging and clinical features of primary and secondary cardiac tumours
- To describe imaging and clinical features of cardiomyopathy including acute myocarditis dilated cardiomyopathy, restrictive and obstructive cardiomyopathy, cardiomyopathy related to systemic disease and infiltrative cardiomyopathy
- To differentiate between ischaemic and non-ischaemic cardiomyopathies
- To describe imaging and clinical features of diabetic and renal heart disease
- To describe age- and gender-related cardiac syndromes, including sudden-death syndromes in young men
- To describe imaging and clinical features of vascular disease including rheumatoid valve disease, stenosis and incompetence of cardiac valves, endocarditis, sub- and supra- valvular disease, subvalvular apparatus disease
- To describe imaging and clinical features of pericardial disease including acute and chronic pericarditis and malignant cardiac disease
- To describe imaging and clinical features of athlete's heart
- To understand the role of CT, MRI and nuclear medicine as well as hybrid imaging in the assessment of inflammatory aortic diseases
- To understand the role of CT and MRI in the assessment of traumatic vascular injuries of the chest
- To describe imaging and clinical features of diseases of the aorta, including coarctation, aneurysm, Marfan's syndrome and aortitis
- To know about acute aortic syndromes, their differential diagnosis and the typical imaging features
- To know about planning prior to minimal invasive valvular repair (TAVI)
- To describe the pathophysiology of pulmonary hypertension and to understand possibilities and limitations of cardiac imaging in this disease
- To know about the role and involvement of the heart in pulmonary hypertension
- To know about cardiac causes of pulmonary hypertension

POST-PROCEDURAL CARDIAC RADIOLOGY

- To describe the pathophysiology, differential diagnoses and treatment of pseudoaneurysm formation following invasive cardiac procedures
- To describe the role of the varying treatments available for both congenital and acquired cardiac disease, including coronary artery disease
- To describe typical imaging and clinical features after coronary bypass grafts, valve replacement, aortic repair, ventricular surgery, pericardiectomy
- To describe the typical findings after surgical treatment of aortic diseases and be familiar with the most common possible complications
- To describe the typical findings after endovascular treatment of aortic diseases and be familiar with the different techniques used (EVAR, TEVAR, FEVAR)
- To classify endoleaks after endovascular aortic repair

- To know national and international organisations dedicated to foster cardiac radiology such as the European Society of Cardiovascular Radiology
- To know standard-of-practice for handling patients with MR conditional pacemakers

SKILLS

- To prepare a patient for cardiac CT including indication, justification, venous access, beta-blocking and vasodilation
- To prepare a patient for cardiac CT including indication, justification, venous access
- To optimise acquisition parameters for cardiac and vascular CT
- To choose optimal post-processing tools for cardiac and vascular CT
- To prepare a patient for cardiac and vascular nuclear medicine and hybrid imaging tests including indication, justification, venous access and medication (e.g. stress testing)
- To optimise acquisition parameters for cardiac and vascular MRI
- To perform quantitative MRI including quality control including T1-, T2-, T2*-mapping, flow measurement, ventricular mass and volume determination
- To identify typical artefacts at cardiac CT, MR, nuclear medicine and hybrid imaging and optimise parameters accordingly
- To choose optimal post-processing tools for cardiac and vascular MRI
- To apply ECG gating for cardiac CT and MRI
- To optimise contrast bolus timing for cardiac CT and MRI
- To perform coronary calcification scoring
- To manage complications in the diagnosis of cardiac disease
- To manage patients undergoing stress testing for cardiac imaging
- To perform post-processing for cardiac and vascular imaging studies, including multiplanar reformations (MPR), maximum intensity projections (MIP), minimum intensity projections (MinIP), volume rendering tools (VRT) and vessel analysis tools
- To perform and present research-related work related to scientific questions and/or evidence-based improvement and quality work in the field of cardiac and vascular radiology
- To critically review the literature and research articles in the field
- To conduct a research study and to evaluate and present the results in a scientific manner
- To understand the potential impact of technological development and learn how to translate results of research into clinical practice

COMPETENCES AND ATTITUDES

- To require minimal supervision from senior colleagues in the routine cardiovascular imaging workflow
- To justify cardiac and vascular CT, MR, nuclear medicine and hybrid imaging examinations for the individual patient situation
- To choose the best-suited method to address specific clinical questions in cardiovascular radiology according to current guidelines
- To communicate with the patient and to obtain informed consent prior to cardiovascular imaging
- To be able to describe and explain the nature of potentially complex radiological tests / procedures in cardiovascular imaging to patients and, where necessary, clinical colleagues
- To choose optimal protocols for CT, MRI and nuclear medicine and hybrid imaging examinations of the heart and vessels
- To create and apply protocols and standard operating procedures to reduce exposure doses for radiological examinations in cardiovascular radiology, nuclear medicine and hybrid imaging
- To supervise and teach technical staff to ensure that appropriate images are obtained for all radiological methods in cardiovascular radiology, nuclear medicine and hybrid imaging
- To judge the quality of imaging examinations in cardiovascular radiology, nuclear medicine and hybrid imaging and to devise strategies to maintain high quality standards
- To link clinical presentations and radiological findings in cardiovascular imaging, nuclear medicine and hybrid imaging with likely diagnosis or, at least, reasoned differential diagnoses
- To construct a concise, informative radiology report in cardiovascular imaging with recommendations for further radiological tests, where appropriate
- To confidently interpret and report CT, MRI, nuclear medicine, hybrid imaging and radiographic examinations in cardiovascular radiology
- To discuss radiological findings with referring physicians at peer level
- To confidently lead the radiological aspects of multidisciplinary team meetings in cardiovascular imaging
- To be able to discuss both routine and more complex cardiovascular imaging cases with radiology colleagues, referring clinicians and patients, also explaining the level of uncertainty of particular cases
- To appreciate and respect the roles and work of other non-medical personnel (including radiographers, nurses, support staff, secretaries etc.) in the cardiovascular imaging unit and communicate with them in a professional manner
- To actively and positively interact with the other specialists of the multidisciplinary team (such as cardiac surgeons, cardiologists etc.), being an integrated member of the team in planning diagnostic studies, therapies and in outcome review
- To prioritise radiological workflow in cardiovascular imaging as based on clinical urgency
- To identify urgent and/or unexpected findings in imaging examinations of the heart and to communicate these timely and properly
- To identify complex cases in cardiovascular imaging in which it is appropriate to obtain a second opinion for interpreting and reporting

- To retrieve current information on state-of-the art procedures in cardiovascular imaging such as guidelines from national and international societies
- To continuously keep abreast of the recent key publications in the field of cardiovascular medicine, pathology and radiology
- To have audit and research skills in cardiovascular imaging
- To present findings and lecture at meetings relevant to cardiovascular imaging
- To teach cardiovascular imaging
- To participate in discussions with other staff regarding operational challenges and potential system solutions regarding the workflow and other aspects of the cardiovascular radiology service

B-III-3

CHEST RADIOLOGY / THORACIC IMAGING

Content provided by ESTI (European Society of Thoracic Imaging)

KNOWLEDGE

- To have an in-depth working knowledge of common respiratory diseases / disorders, including:
 - » Infections of the lungs and pleura
 - » Tumours (benign and malignant of the lungs, pleura, mediastinum and chest wall and vessels)
 - » Airways diseases
 - » Pleural disorders
 - » Diffuse parenchymal lung diseases
 - » Thoracic disorders caused by trauma
 - » Pulmonary disorders in critically-ill patients
 - » Pulmonary disorders occurring following surgery
 - » Congenital disorders of the lungs, airways and mediastinum
 - » Pulmonary arterial (including bronchial arterial) and aortic vascular diseases
 - » Iatrogenic (post-surgical, drug- or radiation-induced) lung disorders
- To have an in-depth knowledge of the aetiologies, epidemiology and prognoses of common respiratory diseases
- To have a core understanding of the key patho-physiological inter-relationships in cardio-pulmonary disease
- To know the common clinical presentations of respiratory disease
- To understand the importance and significance of the following symptoms, signs and/or clinical presentations:
 - » Chest pain (pleuritic or otherwise)
 - » Dyspnoea
 - » Pyrexia (in immunocompetent or immunocompromised hosts)
 - » Massive haemoptysis
 - » Persistent cough (dry or productive)
 - » Wheezing
 - » Recurrent infections or infections 'unresponsive' to treatment
 - » Stridor
 - » Persistent hoarseness
 - » Hypoxia
- To know the correct terminology (based on the 2008 Fleischner Society document) when reporting the radiological signs of pulmonary disease
- To have an in-depth knowledge of the capabilities, limitations and potential detrimental effects of imaging procedures or tests such as guided biopsy, percutaneous drainage, radiofrequency / microwave ablation of intrathoracic tumours
- To be aware of most recent technical advances in the field of thoracic radiology

- To have an in-depth knowledge of the utility and limitations of the following imaging tests:
 - » Plain chest radiography
 - » Computed tomography
 - » PET/CT (PET/MR) and other nuclear medicine techniques (e.g. V/Q scintigraphy, SPECT) including radiotracers used in hybrid imaging
 - » Magnetic resonance imaging
 - » Ultrasound
- To know the local, national and international guidelines or position statements issued by learned societies / bodies, to include but not restricted to the following:
 - » Lung cancer screening guidelines (e.g. US Preventive Services Taskforce Recommendation statement [2013]; American Cancer Society guidelines [2013]; American College of Chest Physicians guidelines [2013]; The NELSON Trial [2013]; The UKLS Lung Screen [2011])
 - » Current Fleischner Society guidelines & recommendations suspected acute pulmonary embolism
The British Thoracic Society Nodule guideline (Callister MEJ et al., Thorax 2015)
 - » Current ATS/ERS idiopathic interstitial pneumonia classification update
- To understand the concepts and concerns related to radiation dose and dose reduction as applied to thoracic imaging
- To have an in-depth knowledge of:
 - » Typical doses in chest radiography and CT (including doses delivered during thoracic intervention)
 - » Typical doses and radiation exposures in hybrid imaging and scintigraphy / SPECT
 - » Units of radiation dose (i.e. milliSieverts [mSv])
 - » The concept of effective dose, computed tomography dose index (CTDI), dose length product (DLP) and the conversion factors for calculation of effective dose from the DLP
 - » The concept of effective dose and dose area product (DAP) for radiographs
 - » Dose reduction techniques in thoracic CT techniques with reference to kilovoltage (kV), tube current-time product (mAs), pitch, automatic exposure control / dose modulation
 - » Low-dose and 'ultralow' dose (sub-millisievert) multidetector CT scanning
 - » Iterative reconstruction techniques
- To understand the following imaging protocols:
 - » CT pulmonary angiography
 - » CT aorta without and with contrast
 - » Staging, treatment, planning and follow-up CT and hybrid imaging (for thoracic malignancies)
 - » High-resolution CT (interspaced HRCT versus volumetric acquisitions)
 - » Low-dose / ultralow dose CT (for follow-up; lung cancer 'screening' studies)
 - » Chest MRI (e.g. in selected patients with chest wall or mediastinal tumours)
- To understand the key difference between urgent findings (some of which might be clinically-unsuspected) and non-urgent findings on thoracic imaging studies and the importance of relaying this information in a timely fashion

- To have an in-depth understanding of the following urgent radiological findings:
 - » Acute pulmonary embolism (including signs of right heart strain)
 - » Acute aortic pathology (including aortic rupture, dissection, intramural hematoma)
 - » Free intraperitoneal air under the diaphragm (in a patient not having undergone recent abdominal surgery)
 - » Large pneumothorax with contralateral mediastinal shift
 - » Significant tracheal narrowing (caused by external compression, intra-tracheal mass)
 - » Impending superior vena caval obstruction by tumour
 - » Widespread opportunistic infection in immunocompromised hosts
- To know the typical imaging signs and patterns of the following neoplastic disorders of the chest:
 - » Lung cancer
 - » Subtypes of lung cancer (small cell versus non-small cell lung cancer)
 - » New classification of adenocarcinomas (incl. atypical adenomatous hyperplasia, adenocarcinoma in situ, minimally invasive adenocarcinoma, invasive adenocarcinoma)
 - » Other thoracic neoplasms (benign and malignant), including mediastinal / tracheal tumours
 - » Lymphoma
 - » Oesophageal cancer
 - » Hamartoma
 - » Tracheal carcinoma
 - » Thymic tumours
 - » Thyroid neoplasms
 - » Mediastinal germ cell tumours
 - » Foregut duplication cysts
 - » Neurogenic tumours
 - » Mediastinal sarcoma
- To know the typical imaging signs and patterns of the following infectious disorders of the chest (including infections in the immunocompromised host & nosocomial pneumonias):
 - » Bacterial
 - » Mycobacterial (tuberculous and non-tuberculous)
 - » Viral
 - » Fungal
 - » Parasitic
- To know the typical imaging signs and patterns of acute and chronic pulmonary thromboembolic disease (and to understand the capabilities and limitations of radiological tests in each)
- To know the typical imaging signs and patterns of the following types of emphysema:
 - » Centrilobular
 - » Paraseptal
 - » Panacinar / panlobular

- To know the typical imaging signs and patterns of the following tracheal diseases:
 - » Tracheal stenosis
 - » Tracheobronchomalacia
 - » Tracheal tumours
- To know the typical imaging signs and patterns of the following bronchial disorders:
 - » Bronchiectasis
 - » Broncholithiasis
 - » Small airways disease (constrictive obliterative bronchiolitis, 'exudative' bronchiolitis)
- To know the typical imaging signs and patterns of pulmonary hypertension
- To know the typical imaging signs and patterns of the following forms of pneumonias / interstitial pneumonias (idiopathic or otherwise):
 - » Usual interstitial pneumonia
 - » Non-specific interstitial pneumonia
 - » Smoking-related interstitial lung diseases
 - » Acute interstitial pneumonia
 - » Organising pneumonia
 - » Lymphoid interstitial pneumonia
- To know the typical imaging signs and patterns of the following other diffuse parenchymal lung diseases:
 - » Sarcoidosis
 - » Hypersensitivity pneumonitis
 - » Cystic lung diseases (Langerhans' cell histiocytosis, tuberous sclerosis / lymphangioliomyomatosis, lymphoid interstitial pneumonia, Birt-Hogg-Dubé disease)
 - » Asbestosis and other occupational lung diseases
 - » Amyloidosis
 - » Alveolar proteinosis
 - » Alveolar microlithiasis
 - » Eosinophilic pneumonias
 - » Vasculitides
 - » Pleuroparenchymal fibroelastosis (see also: Pleural disorders)
 - » Pulmonary haemorrhage syndromes
 - » Drug-induced lung disease
- To know the typical imaging signs and patterns of the following congenital thoracic disorders
 - » Bronchial atresia
 - » Congenital pulmonary adenomatous malformation
 - » Pulmonary sequestration
 - » Congenital lobar emphysema
 - » Pulmonary hypoplasia / agenesis

- To know the typical imaging signs and patterns of the following pleural disorders:
 - » Pleural effusion and empyema
 - » Benign diffuse pleural thickening
 - » Pleural calcification / pleural plaques
 - » Pneumothorax / hydropneumothorax
 - » Bronchopleural fistula
 - » Pleural tumours (pleural fibroma, lipoma, malignant pleural mesothelioma, secondary pleural malignancy [e.g. adenocarcinoma, lymphoma])
 - » Pleuro-parenchymal fibroelastosis (see also: Other diffuse parenchymal diseases)
- To know the typical imaging signs and patterns of the critically-ill patient and/or the patient after major traumatic injury:
 - » Pulmonary oedema (cardiogenic, non-cardiogenic / ARDS)
 - » Position of lines / tubes / catheter and other devices, and complications of misplacement
 - » Barotrauma / pneumothoraces (e.g. signs of tension on mobile plain films)

SKILLS

- To prepare a patient for CT of the chest including indication, justification, and venous access
- To optimise acquisition parameters for chest CT
- To understand and select the optimal post-processing tools for chest CT and hybrid imaging
- To prepare a patient for chest MRI including indication, justification and venous access
- To optimise acquisition parameters for chest MRI
- To identify typical artefacts in radiographic examinations, CT, MRI and hybrid imaging of the chest and to optimise parameters accordingly
- To perform post-processing for chest imaging studies, including multiplanar reformations (MPR), maximum intensity projections (MIP), minimum intensity projections (MinIP), volume rendering tools (VRT) and vessel analysis tools
- To confidently use the correct terminology (based on the 2008 Fleischner Society document) when reporting the radiological signs of pulmonary disease
- To perform ultrasound and/or CT-guided biopsy of lung nodules / masses
- To perform ultrasound and/or CT-guided drainage of intrathoracic collections
- To perform radiofrequency and/or microwave ablation of primary or secondary lung tumours, to understand the indications capabilities and limitations of each technique
- To perform and present research-related work related to scientific questions and/or evidence-based improvement and quality work in the field of chest radiology
- To critically review the literature and research articles in the field
- To conduct a research study and to evaluate and present the results in a scientific manner
- To understand the potential impact of technological development and learn how to translate results of research into clinical practice

COMPETENCES AND ATTITUDES

- To require minimal supervision from senior colleagues in the routine thoracic imaging workflow
- To justify chest imaging examinations for the individual patient situation
- To choose the best-suited method to address specific clinical questions in thoracic radiology according to current guidelines
- To communicate with the patient and to obtain informed consent prior to chest imaging
- To describe and explain the nature of potentially complex radiological tests / procedures in thoracic imaging to patients and, where necessary, clinical colleagues
- To appreciate and respect the roles and work of other non-medical personnel (including radiographers, nurses, support staff, secretaries etc.) in the thoracic imaging unit and communicate with them in a professional manner
- To actively and positively interact with the other specialists of the multidisciplinary team (such as thoracic surgeons, pulmonologists, respiratory therapists etc.), being an integrated member of the team in planning diagnostic studies, therapies and in outcome review
- To choose optimal protocols for radiographic, CT, MRI and hybrid imaging examinations of the chest
- To create and apply protocols and standard operating procedures to reduce exposure doses for radiological examinations in thoracic radiology
- To supervise and teach technical staff to ensure that appropriate images are obtained for all radiological methods in chest radiology
- To judge the quality of imaging examinations in thoracic radiology and to devise strategies to maintain high quality standards
- To link clinical presentations and radiological findings in thoracic imaging with likely diagnosis or, at least, reasoned differential diagnoses
- To construct a concise, informative radiology report in thoracic imaging with, where appropriate, recommendations for further radiological tests
- To confidently interpret and report radiographic CT, MRI and hybrid imaging of the chest
- To discuss radiological findings in respiratory medicine with referring physicians at peer level
- To confidently lead the radiological aspects of multidisciplinary team meetings in thoracic imaging
- To be able to discuss both routine and more complex thoracic imaging cases with radiology colleagues, referring clinicians and patients, also explaining the level of uncertainty of particular cases
- To appreciate and respect the roles and work of other non-medical personnel (including radiographers, nurses, support staff, secretaries etc.) in the thoracic imaging unit and communicate with them in a professional manner
- To prioritise radiological workflow in chest imaging as based on clinical urgency
- To identify urgent and/or unexpected findings in imaging examinations of the chest and to communicate these timely and properly
- To identify complex cases in thoracic imaging, in which it is appropriate to obtain a second opinion for interpreting and reporting
- To retrieve current information on state-of-the-art procedures in thoracic imaging such as guidelines from national and international societies

- To continuously keep abreast of the key recent publications, including international guidelines and position statements (e.g. from the European Respiratory Society, The Fleischner Society, The American Thoracic Society) in the field of respiratory medicine, pathology and radiology
- To have audit and research skills in chest imaging
- To present findings and lecture at meetings relevant to thoracic imaging
- To teach thoracic imaging
- To participate in discussions with other staff regarding operational challenges and potential system solutions regarding the workflow and other aspects of the thoracic radiology service

B-III-4 EMERGENCY RADIOLOGY

Content provided by ESER (European Society of Emergency Radiology)

KNOWLEDGE

NEURO / MAXILLOFACIAL / HEAD & NECK

- To differentiate traumatic from non-traumatic and axial from extra-axial intracranial haemorrhages
- To understand the imaging protocol in evaluating intracranial haemorrhages
- To know the clinical and imaging features of traumatic osseous and non-osseous injuries of the neurocranium and facial bones
- To know the clinical and imaging features of traumatic osseous and soft tissue injuries of the spine, spinal cord, nerve roots and peripheral nerves
- To understand the need for imaging in patients with trauma of the neuroaxis based on up-to-date classifications and test characteristics
- To explain penetrating injury patterns and adequately analyse trajectory / direct injury and complications of indirect injury
- To understand the clinical and imaging features of infectious and inflammatory axial and extra-axial entities and their complications and to know the appropriate imaging techniques (CT, CTA/CTV, MRI including advanced sequences), both within and around the neurocranium, facial bones, neck and spine
- To understand the clinical and imaging features of arterial and venous occlusive disease and sequelae to the brain, with adequate choice of imaging protocol
- To know the typical and atypical fracture patterns in the skull and spine and their respective common and rare associated injuries, explaining their mechanism of injury and understanding appropriate imaging protocols for the low- or high-risk patient
- To understand current clinical and radiological algorithms in emergency neuro-imaging and their implications

CARDIOVASCULAR AND THORACIC IMAGING

- To understand the clinical and imaging features of simple and complicated trauma patterns to the chest
- To know the clinical and imaging features of non-traumatic thoracic emergencies with common and rare acute pathology of the oesophagus lungs, airways and pulmonary vasculature
- To understand the imaging findings and treatment options of traumatic injuries of the thoracic parenchymal structures and pleural spaces and to also know rare traumatic entities
- To know common and rare traumatic and non-traumatic acute pathologies of the cardiovascular and mediastinal structures (heart, pericardium, mediastinum, aorta and branching vessels) and to understand adequate follow-up strategies, including the timely involvement of interventional radiologists for successful non-operative management
- To understand the imaging features of infectious and inflammatory entities and their complications of the lungs, pleural spaces and mediastinum

ABDOMINAL AND GENITO-URINARY IMAGING

- To know the most appropriate imaging modality for traumatic injuries (US, CI, CTA) to parenchymal organs, hollow viscera, peritoneum and retroperitoneum, aorta / major vessel and soft tissues
- To understand the clinical and imaging features of common and rare traumatic injuries to parenchymal organs, hollow viscera, aorta / major vessels and soft tissues and to know the adequate follow-up strategies, including timely involvement of interventional radiologists for successful non-operative management
- To know common and rare non-traumatic emergencies in abdominal imaging including infectious, inflammatory and ischemic entities of the abdominal parenchymal organs, hollow viscera, vascular system and peritoneal lining and their complications
- To differentiate simple and complex pelvic fractures and associated injuries and to know ad-hoc imaging protocol amendments to demonstrate vascular or bladder injury
- To explain imaging strategies in trauma work-up and the up-to-date application of injury grading based on imaging
- To understand spontaneous haemorrhage patterns depending on the organ of origin and the implications for the timeframe of imaging and the interventional radiology treatment
- To differentiate free fluid, fluid collections and abscesses of common and rare aetiologies, both acute and sub-acute / chronic
- To differentiate common and rare acute and sub-acute obstructive entities in the hepatobiliary, genito-urinary and gastrointestinal tracts
- To differentiate normal from abnormal findings in the pregnant patient and the implication in emergency imaging with respect to the imaging protocol
- To understand the clinical and imaging findings of common and rare scrotal acute traumatic and non-traumatic as well as ischemic and inflammatory scrotal pathologies

MUSCULOSKELETAL IMAGING

- To understand the clinical and imaging features of common and rare traumatic skeletal injuries in emergency radiology and to differentiate these from normal variants and non-traumatic osseous pathology (infectious, inflammatory, metabolic, oncologic), in upper and lower extremities as well as the axial skeleton including the pelvis and acetabulum
- To differentiate acute and sub-acute / chronic muscular and musculotendinous injuries in emergency radiology
- To know the clinical and imaging features of common and rare joint dislocations and associated osseous and soft tissue injuries
- To understand the clinical and imaging features of acute traumatic and non-traumatic vascular and nerve pathology

OTHER

- To describe the indications and contraindications for the various imaging examinations in special patient groups
- To understand the radiation burden, risks and protection strategies of different examinations in special patient groups
- To describe the various phases of contrast media application (plain, arterial, portal, delayed, hepatobiliary) and their respective values according to the clinical problem in special patient groups
- To understand key principals of team building and respective roles of team members
- To know key principles in quality assurance and management

SKILLS

- To supervise the triage of all patients that need urgent imaging (in the emergency department as well as in-hospital / critical care)
- To demonstrate active leadership within the different critical care teams (trauma team, resuscitation team, vascular emergency team etc.), specifically in regard to imaging
- To have an adequate level of presentation skills in regard to education in the department, the other departments and conferences
- To supervise technicians performing requested studies to full potential on a per-patient basis (positioning, contrast material, choice of protocol)
- To supervise and encourage radiographers in maximizing their individual performance
- To set up adequate quality assurance schemes for patient care in the emergency department, to reduce radiation dose and maintain adequate image quality
- To interactively lead multidisciplinary team conferences and case-based discussions
- To supervise residents in Level I & II training with respect to diagnostic as well as procedural emergency radiology (and potential complications, e.g. in CT-cystography in trauma)
- To supervise procedures performed by radiology personnel in the acute care setting
- To supervise effective communication of residents with requesting physicians and patients
- To prepare and plan examinations of paediatric and adult patients for any kind of urgent CT or MRI examinations, including ECG-gated scans
- To supervise and explain the proper choice of post-processing tools
- To have an efficiently structured approach to reading massive data volumes acquired in trauma evaluation
- To demonstrate stress tolerance
- To incorporate all available clinical information and to tailor the imaging protocol to the individual needs of patients with pathology possibly arising from multiple organ systems
- To assess complex CT and MRI imaging protocols for image quality, dose reduction, reconstruction algorithm, data handling and storage as well as reporting quality
- To perform and present research-related work related to scientific questions and/or evidence-based improvement and quality work in the field of emergency radiology
- To critically review the literature and research articles in the field
- To conduct a research study, and to evaluate and present the results in a scientific manner

- To understand the potential impact of technological development and learn how to translate results of research into clinical practice
- To perform eFAST (if done at the local institution) or emergency thoracic and abdominal US
- To have experience of femoral artery and venous puncture techniques
- To have experience of image-guided drainage of fluid collections
- To have experience of percutaneous transhepatic drainage of the biliary tract
- To have experience of other interventional emergency procedures under image guidance, particularly in bleeding control
- To confidently identify modality-dependent imaging findings of misplacement of devices such as ventilation, drainage or catheter tubes
- To confidently identify modality- and body-region-dependent common imaging findings in emergency cases such as fracture patterns, ileus signs, free air and fluids, bleedings, infarctions, organ injury
- To confidently classify modality-dependent imaging findings to be potentially acute life-threatening, in principal but not immediately life-threatening, severe but not life-threatening or other
- To confidently classify modality-dependent imaging findings according to curricular content provided by corresponding other subspecialties
- To perform image interpretation or therapy of >2000 emergency cases (>500 CR, >200 eFAST or emergency abdominal US, >500 CT including a wide variety of acute emergency presentations (including >200 polytrauma cases >100 MRI, give evidence of image-guided emergency procedures). These cases have to distribute commonly over the body regions and the typical pathologies
- To interpret, report, communicate and demonstrate common and typical findings
- To interpret, report, communicate and demonstrate rare findings
- To supervise the imaging quality of emergency CT, radiographic and MRI examinations including image post-processing
- To manage procedural complications of imaging in the emergency setting

COMPETENCES AND ATTITUDES

- To confidently differentiate high-risk from low-risk patients before imaging
- To demonstrate an adequate, timely and to-the-point communication with other professionals dealing with acute care
- To confidently differentiate and prioritise findings with respect to their urgency after imaging
- To demonstrate and create meaningful team attitude in the emergency department environment
- To be able to choose and to justify the probably best-suited particular imaging modality and protocol parameters and, if necessary, to properly put imaging techniques into a most appropriate diagnostic pathway considering advances and limitations of the different modalities, diagnostic accuracy and speed, amount of radiation exposure for each patient. This includes considering the patient's age, gender and, where relevant, pregnancy status
- To require minimal supervision from senior colleagues in the emergency radiology routine

- To be an integral and active part of continuous workflow optimisation with particular respect to ethical considerations, improvement of diagnostic accuracy and shortening of the time-to-diagnose / therapy
- To perform actively at multidisciplinary therapy, morbidity and mortality conferences
- To require minimal supervision from senior colleagues in the emergency radiology routine
- To select the optimal imaging method in emergency radiology according to the clinical problem and justify the use of diagnostic imaging examinations and/or interventional procedures
- To choose the best-suited method to address specific clinical questions in emergency radiology according to current guidelines
- To communicate with the patient and to obtain informed consent prior to emergency radiology examinations, if possible
- To describe and explain the nature of potentially complex emergency radiology tests / procedures to patients (if possible) and, where necessary, clinical colleagues
- To demonstrate effective and empathic communication skills in dealing with critically ill patients
- To choose optimal protocols for radiographic, CT, MRI, US and CEUS examinations in emergency radiology
- To create and apply protocols and standard operating procedures to reduce exposure doses for emergency radiology examinations
- To supervise and teach technical staff to ensure that appropriate images are obtained for all emergency radiology methods
- To judge the quality of examinations in emergency radiology and to devise strategies to maintain high quality standards
- To link clinical presentations and emergency radiology findings with likely diagnosis or, at least, reasoned differential diagnoses
- To construct a concise, informative emergency radiology report with, where appropriate, recommendations for further imaging tests
- To confidently interpret and report CT, MRI and radiographic examinations in emergency radiology
- To discuss emergency radiological findings with referring physicians at peer level
- To confidently lead the Emergency Radiology aspects of multidisciplinary team meetings
- To be able to discuss both routine and more complex emergency cases with colleagues, referring clinicians and patients, also explaining the level of uncertainty of particular cases
- To appreciate and respect the roles and work of other non-medical personnel (including radiographers, nurses, support staff, secretaries etc.) in the emergency radiology unit and communicate with them in a professional manner
- To actively and positively interact with the other specialists of the multidisciplinary team in the emergency room, being an integrated member of the team in planning diagnostic studies, therapies and in outcome review
- To prioritise emergency radiology workflow as based on clinical urgency
- To identify complex cases in emergency radiology, in which it is appropriate to obtain a second opinion for interpreting and reporting
- To retrieve current information on state-of-the-art procedures in emergency radiology such as guidelines from national and international societies
- To continuously keep abreast of the key recent publications in the field of emergency radiology

- To have audit and research skills in emergency radiology
- To present findings and lecture at meetings relevant to emergency radiology
- To act as teacher in emergency radiology, at least in a local ER-team
- To participate in discussions with other staff regarding operational challenges and potential system solutions regarding the workflow and other aspects of the emergency radiology service
- To engage in interdepartmental discussions on quality assurance, morbidity, mortality, simulation training (e.g. mass casualty incidence) and logistics
- To communicate timely and properly with patients (if possible), their relatives (if appropriate) and the other medical disciplines involved in order to explain imaging findings, disorders and to rapidly evaluate adequate therapy with respect to best possible outcome
- To appreciate own limitations and to respect the roles and responsibilities of other members of the multidisciplinary emergency team, being an integral part of the team in decision-making

B-III-5

GASTROINTESTINAL AND ABDOMINAL RADIOLOGY

Content provided by ESGAR (European Society of Gastrointestinal and Abdominal Radiology)

KNOWLEDGE**IMAGING TECHNIQUES – GENERAL REQUIREMENTS**

- To describe the indications and contraindications for the various imaging examinations in abdominal imaging to describe the relative costs of the various imaging examinations in abdominal imaging
- To understand the radiation burden and risks of different investigations in abdominal imaging
- To describe the indications and contraindications for enema techniques and the optimal contrast material and technique to be used in each clinical situation
- To list the indications for a contrast-enhanced ultrasound study of the liver
- To describe the techniques for quantification of diseases using ultrasound, CT and MRI, and their clinical role and limitations
- To describe the anatomy of the retroperitoneal structures and the application and limitations of ultrasound in this area
- To list the strengths and limitations of endosonography
- To describe the techniques for CT colonography, CT/MR enterography and CT/MR enteroclysis
- To describe the techniques and role for post-processing images in view of obtaining reformatting, MIP, MinIP, vessel analysis, 3D analysis, including endoluminal reconstructions, fusion images as well as acquisition and postprocessing of functional studies
- To describe the technique of PET/CT (PET/MR), the most important tracers (FDG, choline) and the development of new tracers, and sensitivity and specificity of PET/CT in most common abdominal tumours, including liver metastases of extra-abdominal origin
- To have an in-depth understanding of radiotracers used in hybrid imaging in GI diseases
- To understand the principles and limitations of single and double contrast studies of the gastrointestinal tract and to appreciate their advantages and disadvantages compared with endoscopy
- To describe the main indications, contraindications and basic technique for ablation of liver tumours using ultrasound and/or CT guidance
- To describe the technique and indications for transjugular liver biopsy
- To describe the basic principles of balloon angioplasty and stenting of abdominal visceral arteries for the treatment of stenosis and aneurysms
- To describe the rationale, technique, principle and results of therapeutic embolisation and transarterial chemoembolisation

ANATOMY AND PHYSIOLOGY

- To understand the principal aspects of embryology of the oesophagus, stomach, duodenum, small bowel, appendix, colon, rectum, anus, pancreas, liver, biliary tract and spleen
- To understand the indication and techniques for interventional procedures within the abdomen, including hepatobiliary intervention and luminal stenting
- To have an in-depth knowledge of the anatomy of the pharynx, oesophagus, stomach, duodenum, small bowel, appendix, colon, rectum, anus, pancreas, liver, biliary tract, spleen, mesentery and peritoneum
- To describe the physiology related to the distribution of different tracers in hybrid imaging
- To have an in-depth knowledge of the anatomy of the pelvic floor and abdominal wall
- To describe arterial supply and venous drainage, including important variants, of the various portions of the gastrointestinal tract
- To describe the lymphatic drainage of the relevant organs
- To describe the main anatomical variants that may mimic disease
- To describe normal post-therapeutic imaging related to previous surgery, intervention or radiation therapy
- To describe the various phases of contrast media application (plain, arterial, portal, delayed, hepatobiliary) and their respective values according to the clinical problem

OESOPHAGUS

- To describe the imaging features of oesophageal perforation on plain films and to appreciate the relative role of contrast studies and CT for confirmation
- To describe the imaging features of oesophageal cancer, diverticulum, extrinsic compression, submucosal masses, fistulae, sliding and para-oesophageal hiatus hernia, oesophageal varices, benign strictures, benign tumours, varices, different forms of oesophagitis on contrast studies and CT of the oesophagus
- To understand the significance of Barrett's oesophagus and the clinical manifestations of this disease
- To describe the appearance of common motility disorders
- To have a detailed understanding of the surgical techniques in oesophageal surgery and post-surgical appearances on imaging examinations
- To describe the imaging features of oesophageal cancer on CT and PET/CT and to describe the criteria for non-resectability and lymph node involvement
- To understand the use of endoscopic ultrasound in the staging of oesophageal cancer and the technique of endoscopic ultrasound-guided biopsy

STOMACH AND DUODENUM

- To describe the most appropriate imaging examination and contrast medium use in suspected perforation of the stomach or duodenum and post-operative follow-up and to list the limitations of each examination for these specific conditions
- To understand the role of endoscopic ultrasound and PET or PET/CT in the staging of gastric cancer
- To describe a CT and PET/CT protocol tailored for gastric cancer staging
- To have a detailed understanding of the surgical procedures for the treatment of obesity and the normal post-operative radiological appearance and imaging features of complications
- To have an in-depth understanding of the imaging features of a variety of conditions such as benign and malignant tumours, infiltrative disorders (e.g. linitis plastica), gastric ulcers and positional abnormalities, including gastric volvulus
- To describe the imaging features of duplication cysts of the upper gastrointestinal tract on CT
- To describe the imaging features of rotational abnormalities of the duodenum and the appearance of annular pancreas, submucosal tumours, ampullary tumours and inflammatory disease including ulceration

SMALL BOWEL

- To select the most appropriate imaging examination for small bowel obstruction, inflammatory disease, infiltrative disease, small bowel perforation and ischaemia, cancer, lymphoma, neuroendocrine tumour (NET) and post-operative follow-up and to list the limitations of each examination for these specific cases
- To describe the imaging features of lymphoid hyperplasia of the terminal ileum on small bowel series
- To describe mid-gut positional abnormalities including malrotation, internal hernia and diagnostic features on imaging
- To describe the MRI and CT techniques of enterography and enteroclysis
- To describe the indications for capsule endoscopy and to list the limitations and potential complications of the examination
- To describe imaging features of small bowel abnormalities including stenosis, fold abnormalities, nodules, tumours, ulcerations, wall thickening, marked angulation, extrinsic compression and fistula
- To describe the typical and atypical imaging features of the following small bowel diseases: adenocarcinoma, polyposis, stromal tumour, lymphoma, NET, Crohn's disease, haematoma, Whipple's disease, amyloidosis, radiation-induced injury, malrotation, Meckel's diverticulum, coeliac disease, diverticulosis and systemic sclerosis
- To understand the principles of the interpretation of CT, PET/CT and hybrid imaging examinations in small bowel disease
- To describe the typical findings in various diseases of the small bowel, including the halo sign and the target sign, the transitional zone in small bowel obstruction, small bowel tumours, mural pneumatosis, vascular engorgement, increased density of the mesenteric fat, peritoneal abnormality and malrotation
- To describe the typical and complex imaging features, causes and complications of small bowel obstruction on CT, including the imaging criteria for differentiating simple obstruction from closed-loop obstruction and understand the indications for emergency surgery
- To have an in-depth knowledge of MRI of the small bowel, especially in cases of inflammatory bowel disease

COLON AND RECTUM

- To understand the normal anatomy of the colon, rectum, perirectal tissues and of the anal sphincters
- To describe the optimal imaging examination and outline the technique for study of the colon according to the suspected disease (obstruction, volvulus, diverticulitis, benign tumour, inflammatory disease, cancer, lymphoma, uncommon lesions of the colon and rectum, perforation, post-operative evaluation) and to list the limitations of each technique
- To understand rotational abnormalities of the colon
- To have an in-depth understanding of the imaging appearance of the appendix on CT and ultrasound and of the imaging features of appendicitis and mucocele
- To understand the current indications for CT colonography, including its potential role in colorectal cancer screening
- To describe the appearance of polyps and cancer on CT colonography examinations
- To describe the TNM classification of colorectal cancer and its prognostic value
- To describe the CT, MR and PET/CT imaging features of colon cancer and signs that assess extraluminal disease burden (enlarged lymph nodes, peritoneal carcinomatosis, hepatic metastases)
- To describe the MRI technique for rectal cancer and to have an in-depth understanding of staging of rectal tumours according to the tumour proximity with the mesorectal fascia, distance to the sphincter and to describe the potential limitations of MRI for lymph node staging
- To understand the technique and the value of CT, PET/CT and endosonography in the staging of rectal cancer
- To know the clinical and radiological features of tumour response and progression following chemoradiotherapy and identify the features that support a complete tumour response
- To describe imaging patterns and modalities used to assess for locally recurrent or metastatic colorectal cancer
- To describe the criteria that may help in differentiating between post-operative fibrosis and rectal tumour recurrence in the pelvis
- To describe the role of MRI and PET/CT in staging and restaging anal cancer
- To describe the appearances and differential diagnosis of retrorectal cysts
- To describe the most common diseases of the rectum and the anus and the most frequent operative techniques that may be used to treat them
- To have an understanding of the MRI technique that is used to search for a pelvic / perianal fistula and to describe the appearance of fistulae on MRI
- To describe the appearances of anal sphincter tears and perianal sepsis on endoanal ultrasound
- To describe the basic imaging features of functional and anatomical disorders on both fluoroscopic and MR proctography and the appearance of pelvic floor muscle tears and atrophy using MRI
- To understand the techniques for assessment of colonic transit, the indications and interpretation of transit studies

PERITONEUM AND ABDOMINAL WALL

- To describe the normal features of the peritoneum and omentum on ultrasound, CT and MRI
- To describe the various findings that can be seen in cases of peritoneal disease (nodules, thickening, fluid collection)
- To describe the various types of abdominal wall hernias (inguinal, femoral, umbilical, Spigelian, parastomal, post-operative) on CT and on ultrasound
- To describe the imaging features of pelvic hernias (obturator, sciatic, perineal) on CT
- To describe the imaging features of hernial strangulation on CT and on ultrasound
- To describe the imaging features of mesenteric tumour and its location on ultrasound, CT, PET/CT and MRI
- To describe the imaging features of mesenteric cysts on ultrasound, CT and MRI
- To describe the imaging features of rectus sheath hematoma on ultrasound, CT and MRI
- To describe the imaging features of ascites on ultrasound, CT and MRI and to describe the features of loculated ascites
- To describe the imaging features and basic clinical features of the following peritoneal diseases on CT, PET/CT and MRI: peritonitis, peritoneal carcinomatosis, peritoneal tuberculosis, mesenteric lymphoma, mesenteric panniculitis, desmoid tumour, epiploic appendagitis and omental infarction

VESSELS

- To understand the basic principles of Doppler ultrasound and superior mesenteric artery stenosis or occlusion
- To understand the use of Doppler ultrasound to assess the patency of and the direction of flow in the portal and hepatic veins
- To describe the imaging appearance in vasculitis on CT, PET/CT and MRI
- To describe the respective roles of angiography and CT angiography in diagnosis and management of acute gastrointestinal haemorrhage
- To describe the angiographic and CT appearances of acute haemorrhage and to describe the advantages and limitations of the techniques
- To describe the imaging appearance of small bowel ischaemia / infarction on CT
- To describe the angiographic imaging features of occlusion, stenosis and aneurysms of the mesenteric arteries

LIVER

- To have a detailed understanding of liver anatomy and segmentation and vessel anatomy (hepatic artery, portal vein, hepatic veins, inferior vena cava), including variants in vascular anatomy that may affect surgical planning
- To have an in-depth knowledge of the most common surgical procedures for hepatectomy and liver transplantation
- To have an in-depth knowledge of the imaging features and basic clinical features of vascular diseases of the liver, including Budd–Chiari Syndrome, Osler–Weber disease, portal thrombosis, peliosis, sinusoidal obstruction syndrome and toxic diseases (treatment-induced)

- To describe the most appropriate imaging examination for the characterisation of liver lesions and to describe the typical and atypical (with haemorrhagic transformation) imaging features of focal liver lesions on ultrasound, CT, PET/CT and MRI (including hepato-biliary contrast agents)
- To describe the typical or atypical (with haemorrhagic transformation) imaging features of biliary cysts on ultrasound, CT and MRI
- To describe the imaging features of typical and complicated hydatid cysts on ultrasound, CT and MRI
- To differentiate between amoebic abscess and pyogenic abscess of the liver with regard to appearance, evolution, treatment, and indication for drainage
- To describe the imaging features of liver haemangiomas on ultrasound (including ultrasound contrast agents), CT and MRI including typical and atypical cases
- To have an in-depth knowledge of the imaging features of typical and atypical focal nodular hyperplasia and liver cell adenoma including subtypes
- To describe the qualitative and quantitative imaging features of homogeneous and heterogeneous liver steatosis
- To describe the imaging features of homogeneous and heterogeneous liver steatosis on ultrasound, CT and MRI (including imaging quantification)
- To have an in-depth knowledge of the natural history of hepatocellular carcinoma (HCC) and the major techniques and the indications for treatment (surgical resection, chemo- or radioembolisation, percutaneous ablation, liver transplantation, oral targeted therapy, radiotherapy)
- To have an in-depth knowledge of the typical and atypical (e.g hypovascular) imaging features of HCC
- To have an in-depth knowledge of the staging of HCC, in order to discuss indications for treatment
- To have an in-depth knowledge of the typical and atypical imaging features of liver metastases and to describe the sensitivity and specificity of each imaging modality
- To describe the imaging features of peripheral cholangiocarcinoma and to describe the staging and consequences for management (surgery, palliation)
- To have an in-depth knowledge of the morphological changes associated with liver cirrhosis, including lobar atrophy or hypertrophy, regeneration nodules, fibrosis and the effects of portal hypertension elsewhere in the abdomen and pelvis
- To list the main causes of liver cirrhosis
- To have an in-depth knowledge of the principles and methods for fibrosis quantification using ultrasound and MRI
- To describe rare tumours of the liver and their radiological appearance
- To have an in-depth knowledge of the imaging appearance and the different methods for quantification of liver iron overload
- To have an in-depth knowledge of the technique for percutaneous image-guided liver biopsy and its indications
- To have an in-depth knowledge of the complications of percutaneous image-guided liver biopsy and to know the frequency and causes for procedure-related morbidity and mortality
- To have an in-depth knowledge of the role of hepato-biliary contrast media
- To have a detailed understanding of the current application of diffusion-weighted imaging of the liver
- To describe the imaging features of acute and portal vein thrombosis and cavernous transformation of the portal vein

- To differentiate between bland and neoplastic portal vein thrombosis
- To describe the changes in liver morphology as a result of chronic portal vein thrombosis and cavernous transformation of the portal vein
- To describe the imaging features of those disorders associated with non-cirrhotic portal hypertension, such as schistosomiasis and idiopathic non-cirrhotic portal hypertension
- To recognise the imaging features and learn the physiopathology of benign liver lesions associated with vascular liver injuries

BILIARY TRACT

- To know the strengths and weaknesses of different imaging methods for the detection of gall bladder and common bile duct stones
- To describe the imaging features and clinical features of acute cholecystitis on ultrasound (including Doppler) and CT
- To describe unusual features of cholecystitis like gangrenous, emphysematous and acalculous cholecystitis on ultrasound and CT
- To list the causes of gallbladder wall thickening on ultrasound
- To describe the imaging features of gallbladder cancer on ultrasound, CT and MRI
- To describe the imaging features of gallbladder adenomyomatosis on ultrasound, CT and MRI
- To describe the staging of gallbladder tumours on ultrasound and CT
- To describe the imaging features of cholangiocarcinoma of the liver hilum (Klatskin's tumour) and to describe the tumour staging, with regard to treatment options (resectability, indication for palliation)
- To describe the imaging features of an ampullary carcinoma on ultrasound, CT and MRI, including magnetic resonance cholangiopancreatography (MRCP) and endoscopic ultrasound
- To describe the typical imaging features of sclerosing cholangitis on ultrasound, CT and MRI, including MRCP; to know the natural history and possibility of associated cholangiocarcinoma and indications for treatment and indications for biliary tract opacification
- To describe the main techniques for surgery of the bile duct and its common complications
- To describe the imaging features of biliary leaks on imaging examinations including specific contrast-enhanced MRI examinations
- To describe the imaging features of the spectrum of disorders originating from ductal plate malformation, including congenital hepatic fibrosis, biliary hamartomas, Caroli's disease and polycystic liver disease
- To describe the imaging features of choledochal cyst on ultrasound, CT and MRI

PANCREAS

- To describe the natural history of chronic pancreatitis and to list the common causes
- To describe the imaging features of pancreatic calcifications on plain films, ultrasound and CT
- To describe the anatomical variants of the pancreatic duct (e.g. annular pancreas) and the imaging methods used to diagnose it
- To list the indications and rationale for functional examinations of the pancreas (e.g. MRCP following secretin stimulation)
- To describe the value of clinico-biological (Ranson score, APACHE II) and CT (Balthazar's CT severity score) methods for the grading of acute pancreatitis
- To describe the typical imaging features of pancreatic and peri-pancreatic collections in the case of acute pancreatitis: acute peripancreatic fluid collection and pseudocyst for interstitial oedematous pancreatitis, acute necrotic collection and walled-off necroses for necrotizing pancreatitis
- To describe the typical and atypical imaging features of pancreatic adenocarcinoma on ultrasound, CT, MRI and endoscopic ultrasound
- To describe the tumour staging for pancreatic adenocarcinoma including criteria for non-resectability

- To describe the typical imaging features of cystic tumours of the pancreas, including serous and mucinous cystadenoma, intraductal mucinous tumours and rare cystic tumours, the indications and modalities used for tumour characterisation and the indication for follow-up imaging for IPMN
- To describe the main techniques for pancreatic surgery and to list their potential complications
- To describe the imaging features of a pancreatic pseudocyst and to discuss the advantages and limitations of different treatments (follow-up, interventional procedure, percutaneous or endoscopic surgery)

SPLEEN

- To describe optimal imaging strategies for the spleen according to the indication (e.g. trauma, staging of lymphoproliferative disorders, investigation of a focal lesion etc.)
- To list the causes and imaging features of focal splenic abnormalities, including infection and both benign and malignant masses
- To describe the causes of splenic calcification
- To list the causes of splenic enlargement

SKILLS

- To choose the most appropriate imaging examination according to the clinical problem in abdominal imaging
- To choose the most suitable contrast material and its optimal use according to the imaging technique and the clinical problem
- To perform video-fluoroscopy of the swallowing mechanism
- To perform contrast studies of the upper gastrointestinal tract with the most appropriate contrast material
- To perform both single and double contrast studies as well as motility assessments of the upper gastrointestinal tract
- To perform small bowel follow-through and enteroclysis, including catheter placement beyond the ligament of Treitz
- To perform a single contrast enema
- To catheterise a stoma for colon opacification and to perform pouchograms and loopograms
- To confidently plan a CT or PET/CT examination of the abdomen and to tailor it to the individual situation in regard to intravenous contrast medium, rate of injection, dose and delay after contrast medium injection and the type and method of intraluminal contrast medium application, with a radiation dose as low as reasonably achievable
- To confidently plan an MRI examination of the upper abdomen and to tailor it to the individual situation with regard to the potential use of intravenous contrast medium, rate of injection, dose and delay after contrast medium injection, type and method of intraluminal contrast medium, magnetic resonance cholangiopancreatography (MRCP) and quantification of liver fat / iron
- To confidently plan MRI examinations of the small bowel, rectum and anal canal and to adapt it to the individual situation, including the application of intraluminal contrast
- To perform CT and MR examinations for recognising the anatomical variants of the pancreatic duct (e.g. annular pancreas)

- To apply techniques for quantification of diseases using ultrasound, CT, PET/CT and MRI, based on an in-depth understanding of their clinical role and limitations
- To perform MRI and CT enterography and enteroclysis
- To perform ultrasound examinations of the liver, gall bladder, biliary tree, pancreas and spleen
- To perform duplex Doppler examinations of the abdominal vessels, recognising the normal findings of the duplex Doppler study of the hepatic artery, superior mesenteric artery, portal vein and hepatic veins
- To perform ultrasound examinations of the gastrointestinal tract and to identify the various portions (stomach, duodenum, small bowel, appendix and colon)
- To perform ultrasound examinations of the abdomen in patients with suspected inflammatory bowel disease
- To perform contrast-enhanced ultrasound examinations of the liver
- To perform CT colonography
- To perform basic and advanced post-processing tasks for abdominal imaging studies, including maximum intensity projections (MIP), minimum intensity projections (MinIP), volume rendering, vessel analysis tools, endoluminal reconstructions and fusion images
- To perform and present research-related work related to scientific questions and/or evidence-based improvement and quality work in the field of gastrointestinal and abdominal radiology
- To critically review the literature and research articles in the field
- To conduct a research study and to evaluate and present the results in a scientific manner
- To understand the potential impact of technological development and learn how to translate results of research into clinical practice

Competency in all of the following interventional procedures is unlikely to be achieved by many radiologists.

Level III competency requires an understanding of the technique, indication and complications related to all of the procedures listed below. In addition, independent practice may be achieved in one or more of the following:

- To perform percutaneous image-guided liver biopsy
- To perform biopsy of abdominal tumours under ultrasound or CT guidance
- To drain abdominal abscesses under ultrasound or CT guidance
- To perform image-guided interventions in colon cancer, e.g. colonic stent placement in the case of colonic obstruction
- To perform percutaneous gastrostomy under image guidance
- To perform percutaneous cholecystostomy
- To perform percutaneous biliary interventions
- To perform radiologically guided stenting of the biliary system and gastrointestinal system, using polytetrafluoroethylene and expandable metal stents
- To perform ablation of liver tumours using ultrasound and/or CT guidance
- To perform transjugular liver biopsies
- To perform balloon angioplasty and stenting of the mesenteric arteries for the treatment of stenosis and aneurysms
- To perform transarterial chemoembolisation and simple embolisation for acute abdominal bleeding control
- To perform radioembolisation procedures of the liver

COMPETENCES AND ATTITUDES

- To confidently justify diagnostic imaging examinations and/or interventional procedures of the abdomen and/or gastrointestinal system
- To confidently choose the best method for evaluating disorders of the abdomen and/or gastrointestinal system
- To communicate with the patient in order to obtain informed consent prior to diagnostic imaging and interventional procedures of the abdomen and/or gastrointestinal system
- To confidently choose optimal imaging parameters for radiographic, ultrasonographic, CT, PET/CT and MRI examinations of the abdomen and/or gastrointestinal system
- To confidently apply techniques to reduce exposure doses for radiographic and CT and PET/CT examinations of the abdomen
- To confidently design imaging protocols and standard operating procedures for CT and PET/CT examinations of the abdomen and gastrointestinal system, including the appropriate application of intravenous and/or intraluminal contrast, spatial and temporal resolution, and inspiration / expiration / breath-hold techniques
- To confidently design imaging protocols and standard operating procedures for MRI examinations of the abdomen, pelvis and gastrointestinal system, including the appropriate application of intravenous and/or intraluminal contrast, spatial and temporal resolution, and inspiration/expiration/breath-hold techniques
- To supervise and teach technical staff to ensure that appropriate images are obtained
- To confidently judge the quality of the imaging examinations in abdominal imaging and to devise strategies to improve image quality
- To confidently report abdominal radiographs in cases of acute abdomen
- To confidently interpret and report abdominal radiographs, ultrasonographic examinations, abdominal CT studies and MRI examinations of the upper abdomen, small bowel, rectum and anal canal
- To report oncological studies of the abdomen according to international standards (RECIST, WHO) applicable to the specific situation
- To appreciate own limitations and to identify when it is appropriate to obtain assistance in interpreting and reporting images of the abdomen and gastrointestinal system
- To confidently identify urgent and/or unexpected findings in imaging examinations of the abdomen and gastrointestinal system and to communicate these timely and properly
- To communicate with patients and their relatives in order to explain their imaging findings of the abdomen and gastrointestinal system
- To perform multidisciplinary conferences and tumour boards for diseases of the abdomen and gastrointestinal system

B-III-6 HEAD AND NECK RADIOLOGY

Content provided by ESHNR (European Society of Head and Neck Radiology)

KNOWLEDGE

- To have an in-depth knowledge of the normal anatomy of the head and neck, including the skull base, cranial nerves, temporal bone, paranasal sinuses, the oral cavity, pharynx and larynx, the middle and inner ear, salivary glands, thyroid and parathyroid glands, thoracic inlet, orbit, teeth, mandible and temporomandibular joint, lymph nodes, arterial and venous system, and the neck including deep spaces and compartments as demonstrated by CT, cone beam CT (CBCT), US, MRI, angiography, video-fluoroscopy, conventional radiographs, PET/CT and PET/MRI
- To have an in-depth knowledge of normal variants of the head and neck, including paranasal sinuses, oral cavity, pharynx and larynx, temporal bone, skull base, orbit, teeth, temporomandibular joint, thyroid and parathyroid, salivary glands, neck and thoracic inlet
- To have an in-depth knowledge of clinical practice relevant to pathologic conditions of the head and neck and how to investigate these according to the latest recommendations and state of the art protocols
- To have an in-depth knowledge of the mean exposure doses of CT, cone beam CT (CBCT), conventional radiography, X-ray angiography, X-ray-guided interventional procedures, radionuclide imaging and PET/CT
- To have an in-depth knowledge of common and rare diseases of the eye and orbit, temporal bone and skull base, cranial nerves, paranasal sinuses, thyroid, parathyroid and salivary glands, teeth, temporomandibular joints and mandible, pharynx and larynx, lymph nodes, vessels and soft tissues in the head and neck, thoracic inlet including the brachial plexus and deep spaces
- To have an in-depth knowledge role of ultrasound- and/or CT-guided puncture of salivary glands, lymph nodes, thyroid gland and other head and neck masses
- To have an in-depth knowledge of the role, advantages and disadvantages of CT, ultrasound, cone beam CT, video-fluoroscopy and MRI applications in the head and neck
- To have an in-depth knowledge of the anatomy of the arterial and venous system and its relevance to interventional radiology
- To describe the principles of CT, CBCT, MRI with DWI, US, PET/CT and image processing pertinent to traumatic, inflammatory, infectious, neoplastic and congenital conditions of the head and neck and to understand the principle of newer AI tools and their potential benefit in the head and neck
- To understand the role and applications of radiotracers used in hybrid imaging in head and neck radiology
- To know the TNM classification of head and neck tumours and imaging-related issues
- To fully master the terminology for describing the site of lymph nodes in the head and neck region

TEMPORAL BONE

- To confidently list, describe and differentiate common and uncommon imaging features of congenital disorders leading to deafness (e.g. cochlear aplasia / hypoplasia, Mondini malformation, large endolymphatic sac anomaly (LESA) / large vestibular aqueduct syndrome (LVAS))
- To have in-depth knowledge of the imaging features and clinical features of disorders leading to secondary deafness including otosclerosis, Menière's disease, temporal bone inflammatory disease and tumours of the cerebellopontine angle
- To confidently delineate the course of cranial nerves VI - XI in their different components
- To have in-depth knowledge of:
 - » the imaging and clinical features of cholesteatoma and other inflammatory lesions
 - » the imaging and clinical features of traumatic lesions and fractures of the temporal bone
 - » the imaging and clinical features of tumours of the temporal bone and cerebellopontine angle and to distinguish these from each other
- To confidently differentiate different pathologies of the external auditory canal, including atresia and tumours
- To differentiate different pathologies of the middle ear
- To be familiar with the different types of cochlea implants and their respective MRI compatibility / non-compatibility (including specific precautions)
- To know the various causes of vascular tinnitus and to describe their respective imaging features

FACIAL SKELETON, SKULL BASE AND CRANIAL NERVES

- To list the different neoplasms of the clivus and to describe their respective imaging appearance, including meningioma, macroadenoma, chordoma, chondrosarcoma and others
- To confidently describe the imaging and clinical features of lesions of the jugular foramen, including glomus tumour / paraganglioma, jugular bulb pseudolesions, jugular bulb diverticulum, dehiscent jugular bulb, jugular foramen schwannoma, jugular foramen meningioma and others
- To confidently describe the imaging features and clinical features of diffuse diseases of the skull base, including fibrous dysplasia, plasmocytoma, Langerhans cell histiocytosis, chondrosarcoma and metastases
- To have in-depth knowledge of the normal anatomy and function of the cranial nerves and to list common and less common pathologies
- To list and categorise traumatic lesions of the facial skeleton and skull base and to be familiar with complications and therapeutic consequences
- To describe the typical imaging features of neoplasms of the mandible and maxilla
- To have in-depth knowledge of the imaging features of jaw lesions including cysts and cyst-like lesions
- To have in-depth knowledge of the imaging features of infectious and inflammatory lesions of the mandible, maxilla and skull base, including osteomyelitis, osteoradionecrosis and bisphosphonate osteonecrosis

ORBIT AND VISUAL PATHWAYS

- To have in-depth knowledge of:
 - » the imaging and clinical features of congenital lesions of the orbit, including coloboma
 - » the imaging and clinical features of typical tumours of the orbit in children including dermoid and epidermoid cysts, cavernous haemangioma, lymphangioma, rhabdomyosarcoma and retinoblastoma
 - » the orbital manifestations of neurofibromatosis type I and other congenital diseases
 - » the imaging and clinical features of infectious and inflammatory disorders of the orbits including optic neuritis, abscesses, sarcoidosis and idiopathic inflammatory disorders
 - » the imaging and clinical features of benign tumours of the orbits in adults including meningioma, optic / chiasmal glioma, orbital haemangioma and benign mixed tumour of the lacrimal gland
 - » the imaging and clinical features of malignant tumours of the orbits in adults including ocular melanoma, orbital lymphoma, higher grade optic / chiasmal glioma, adenoid cystic carcinoma of the lacrimal glands

NOSE, NASOPHARYNX AND PARANASAL SINUSES

- To confidently describe the imaging and clinical features of congenital lesions of the paranasal sinuses including choanal atresia and frontoethmoidal encephalocele
- To differentiate normal variants of the nose and paranasal sinuses from pathology
- To confidently describe the imaging and clinical features of infectious and inflammatory disorders of the nose and paranasal sinuses including acute and chronic rhinosinusitis, fungal sinusitis, sinonasal polyposis, sinonasal mucocele and sinonasal Wegener granulomatosis
- To be knowledgeable of typical complications of infectious and inflammatory disorders of the nose and paranasal sinuses
- To list and describe the typical surgical approaches to the nose and paranasal sinuses including functional endoscopic sinus surgery (FESS)
- To have an in-depth knowledge of the imaging and clinical features of benign and malignant neoplasms of the nose and paranasal sinuses including inverted papilloma, juvenile angiofibroma, sinonasal hemangioma, sinonasal osteoma, sinonasal fibrous dysplasia, sinonasal squamous cell carcinoma, sinonasal adenocarcinoma, sinonasal melanoma, esthesioneuroblastoma, sinonasal lymphoma and others
- To describe the typical imaging features of the nose and paranasal sinuses after surgery
- To describe the imaging features and clinical features of the nasopharyngeal pathologies including Thornwaldt cyst, inflammatory and infectious lesions and neoplasms

MASTICATOR SPACE, PAROTID SPACE AND CAROTID SPACE

- To have an in-depth knowledge of:
 - » the anatomical delineations of the masticator space, parotid space and carotid space
 - » pseudolesions of the masticator space, including denervation atrophy, benign muscle hypertrophy and asymmetries of the pterygoid venous plexus
 - » the typical and rare imaging features of abscess formations of the masticator space
 - » the imaging features and clinical features of benign and malignant neoplasms of the masticator space including peripheral nerve sheath tumours of the trigeminal nerve
 - » the imaging features and clinical features of infectious and inflammatory lesions of the parotid space including parotitis, Sjogren syndrome and benign lymphoepithelial lesions in patients with HIV
 - » the imaging features and clinical features of benign and malignant neoplasms of the parotid space including Warthin tumour, benign mixed tumour, adenoid cystic carcinoma, mucoepidermoid carcinoma, lymphoma, lymph node metastases and malignant tumours of the skin
 - » the imaging features and clinical features of vascular lesions of the carotid space including ectatic carotid arteries, carotid artery pseudoaneurysm, carotid artery dissection and jugular venous thrombosis
 - » the imaging features and clinical features of neoplasms of the carotid space including carotid body paraganglioma, glomus vagale paraganglioma, schwannoma and neurofibroma and to know the use of radiotracers for the work up of these lesions on hybrid studies

LYMPH NODES OF THE HEAD AND NECK REGION

- To have an in-depth understanding of the nomenclature of the lymph nodes and nodal regions and implications for TNM staging
- To confidently describe the imaging features and clinical features of infectious and inflammatory disorders of the lymph nodes including reactive lymph node enlargement, suppurative lymph nodes, Kimura disease, Castleman disease and others
- To describe the imaging features and clinical features of neoplastic disorders of the lymph nodes, including lymphoma (Hodgkin and Non-Hodgkin) and nodal metastases
- To have an in-depth understanding of new imaging modalities and techniques including diffusion-weighted imaging, perfusion, PET/CT and elastography

ORAL CAVITY, OROPHARYNX AND RETROPHARYNGEAL SPACE

- To have an in-depth knowledge of:
 - » the imaging features and clinical features of congenital lesions of the oral cavity and oropharynx, including dermoid and epidermoid cysts, accessory salivary tissue, lymphangioma and lingual thyroid gland
 - » the imaging features and clinical features of inflammatory and infectious lesions of the oral cavity and oropharynx, including abscesses, retention cysts, sialoceles, sialadenitis and ranula
 - » the imaging features and clinical features of benign and malignant neoplasms of the oral cavity and oropharynx, including benign mixed tumours, squamous cell carcinoma, malignant tumours of the minor salivary glands
 - » the typical imaging features and clinical presentation of retropharyngeal abscesses

HYPOPHARYNX, LARYNX AND CERVICAL OESOPHAGUS

- To have an in-depth knowledge of:
 - » the imaging features and clinical features of neoplasms of the hypopharynx and larynx, including squamous cell carcinoma of the hypopharynx, of the supraglottic, glottic and subglottic regions, chondrosarcoma and other malignant tumours of the larynx
 - » the typical imaging features of the hypopharynx and larynx after surgery and after radiation therapy
 - » the imaging features of vocal cord paralysis
 - » the potential effects and the respective imaging features of laryngeal trauma
 - » the imaging features, causes and clinical consequences of tracheal stenoses
 - » the imaging features of laryngoceles and pharyngoceles, webs and strictures
 - » functional abnormalities of the larynx and hypopharynx during impaired swallowing including primary and secondary aspiration and dysfunction of the cricopharyngeal muscle
 - » the imaging features and clinical features of cervical oesophageal carcinoma
 - » the imaging features and clinical features of a Zenker diverticulum and the typical approaches to therapy
- To have a thorough understanding of PET/CT and PET/MRI findings in head and neck tumours involving the pharynx, larynx and oral cavity, common pitfalls and to understand the potential role of new tracers and their application in head and neck oncology

THYROID AND PARATHYROID GLANDS

- To describe the imaging and clinical features of thyroiditis and goiter, and of benign and malignant neoplasms of the thyroid and parathyroid glands, including thyroid and parathyroid adenomas, different types of thyroid carcinoma and thyroid lymphoma
- To describe the most important findings of Tc-99m-scintigraphy and PET/CT in various diseases of the thyroid gland

CONGENITAL AND TRANSSPATIAL LESIONS

- To have an in-depth understanding of the embryology of the head and neck region
- To confidently describe the imaging features and clinical features of branchial cleft cysts
- To confidently describe the imaging features and clinical features of thyroglossal duct cysts
- To describe the imaging features and clinical features of thymus cysts
- To have an in-depth knowledge of the imaging features and clinical features of vascular lesions including malformations of the head and neck region
- To confidently describe the imaging manifestations of neurocutaneous syndromes, including neurofibromatosis type I, in the head and neck region
- To describe the imaging features and clinical features of fibromatosis colli

SKILLS

- To confidently plan and protocol contrast enhanced CT, CBCT, MRI and PET/CT for the evaluation of pathologic conditions of the head and neck
- To understand and to confidently adapt the parameters of MRI sequences in order to avoid poor quality images and to obtain the information necessary for the diagnosis in head and neck imaging
- To perform the 2D and 3D reconstructions necessary for the interpretation / illustration of findings as well as more advanced post-processing techniques including multimodality data fusion and multiple layers reconstructions and post-processing of perfusion maps
- To perform independently video-fluoroscopy of deglutition, US, US-guided FNAC, CT-guided FNAC or US-/CT-guided biopsy, dacryocystography or fistulography

COMPETENCES AND ATTITUDES

- To require no supervision from senior colleagues in the routine head and neck imaging workflow
- To confidently select the optimal imaging method for imaging disorders of the head and neck according to the clinical problem and justify the use of diagnostic imaging examinations and/or interventional procedures
- To justify when and why a particular examination needs to be performed in the head and neck
- To choose the best-suited method to address specific clinical questions in head and neck radiology according to current guidelines
- To confidently communicate with the patient and to obtain informed consent prior to head and neck imaging
- To describe and explain the nature of potentially complex radiological tests / procedures in head and neck imaging to patients and, where necessary, clinical colleagues
- To choose the optimal protocols for radiographic, CT, MRI and hybrid imaging examinations of the head and neck
- To apply techniques to reduce exposure doses for CT, CBCT, video-fluoroscopy of deglutition, angiography and X-ray-guided procedures in head and neck imaging
- To create and apply protocols and standard operating procedures to reduce exposure doses for radiological examinations in head and neck radiology
- To supervise and teach technical staff to ensure that appropriate images are obtained for all radiological methods in head and neck radiology
- To judge the quality of imaging examinations in head and neck radiology and to devise strategies to maintain high quality standards
- To link clinical presentations and radiological findings in head and neck imaging with likely diagnosis or, at least, reasoned differential diagnoses
- To construct a concise, informative radiology report in head and neck imaging with, where appropriate, recommendations for further radiological tests
- To confidently interpret and report radiographic CT, MRI and hybrid imaging examinations of the head and neck
- To discuss radiological findings in otorhinolaryngology with referring physicians at peer level
- To confidently lead the radiological aspects of multidisciplinary team meetings in head and neck imaging

- To be able to discuss both routine and more complex head and neck imaging cases with radiology colleagues, referring clinicians and patients, also explaining the level of uncertainty of particular cases
- To appreciate and respect the roles and work of other non-medical personnel (including radiographers, nurses, support staff, secretaries etc.) in the head and neck imaging unit and communicate with them in a professional manner
- To actively and positively interact with the other specialists of the multidisciplinary head and neck team (such as ENT surgeons, audiologists, phoniatrists etc.), being an integrated member of the team in planning diagnostic studies, therapies and in outcome review
- To prioritise radiological workflow in head and neck imaging as based on clinical urgency
- To identify urgent and/or unexpected findings in imaging examinations of the head and neck and to communicate these timely and properly
- To identify complex cases in head and neck imaging, in which it is appropriate to obtain a second opinion for interpreting and reporting
- To retrieve current information on state-of-the art procedures in head and neck imaging such as guidelines from national and international societies
- To continuously keep abreast of the key recent publications in the field of head and neck medicine, pathology and radiology and applications of newer AI techniques
- To have audit and research skills in head and neck imaging
- To present findings and lecture at meetings relevant to head and neck imaging
- To teach head and neck imaging
- To participate in discussions with other staff regarding operational challenges and potential system solutions regarding the workflow and other aspects of the head and neck radiology service

B-III-7 **INTERVENTIONAL RADIOLOGY**

See European Curriculum and Syllabus for Interventional Radiology – second edition

Available under: <https://www.cirse.org/education/curricula/>

B-III-8

MUSCULOSKELETAL RADIOLOGY

Content provided by ESSR (European Society of Musculoskeletal Radiology)

KNOWLEDGE

- To have an in-depth knowledge of the anatomy and physiology of bones and joints (both synovial and non-synovial) of the upper extremities, lower extremities and pelvis
- To have an in-depth knowledge of the anatomy of the axial skeleton (i.e. cervical, thoracic, and lumbosacral spine), intrinsic back muscles and related soft tissues (e.g. discs, ligaments, spinal nerves)
- To have an in-depth knowledge of the anatomy of the soft tissue structures that are pertinent to the musculoskeletal system (e.g. tendons, muscles, nerves, ligaments, fascial planes, vessels and connective tissue spaces) in the upper extremity, lower extremity, pelvis, thoracic cage, abdominal wall and neck
- To have a basic knowledge of biomechanics and pathophysiology of the muscle-tendon-bone unit
- To understand the main stages of skeletal maturation in the paediatric age group
- To know the most common anatomical variants in musculoskeletal imaging
- To describe congenital and developmental anomalies of the skeleton and soft tissue structures that are pertinent to the musculoskeletal system
- To have an in-depth understanding of the clinical and imaging presentations of traumatic injuries of the axial and appendicular skeleton, including:
 - » Common and uncommon fractures
 - » Common and uncommon dislocations
 - » Physiological fracture healing
 - » Complications of fracture healing including delayed union, malunion and non-union
 - » Complex regional pain syndrome
- To understand the basic mechanisms of traumatic injury to the axial and appendicular skeleton
- To understand the differentiating criteria between stable and unstable injuries
- To have an in-depth understanding of the clinical and imaging presentations of overuse pathologies of the axial and appendicular skeleton, including:
 - » Labral tears
 - » Shoulder impingement syndromes
 - » Overuse tendinopathies and tears
 - » Retinacula-related disorders
 - » Exertional compartment syndromes

- To have an in-depth understanding of the clinical and imaging presentations of arthropathies and neurologic / muscular disorders and connective tissue diseases of the axial and appendicular skeleton, including:
 - » Rheumatoid arthritis
 - » Psoriatic arthritis and psoriatic spondyloarthropathy
 - » Ankylosing spondylitis
 - » Scleroderma
 - » Systemic lupus erythematosus
 - » Mixed connective tissue disease
 - » Juvenile idiopathic arthritis
 - » Idiopathic inflammatory myopathy
 - » Gout
 - » Crystal-related arthritis
 - » Neuropathic osteoarthropathy
- To have an in-depth understanding of the clinical and imaging presentations (including radiography, ultrasound, CT, MRI, nuclear medicine studies, hybrid imaging) of infection and non-infectious complications of joint prostheses
- To have an in-depth understanding of the clinical and imaging presentations of infectious disorders of the axial and appendicular skeleton, including:
 - » Cellulitis
 - » Pyomyositis
 - » Abscess
 - » Septic arthritis
 - » Diabetic pedal infection
 - » HIV-related atypical mycobacterial infections
- To have an in-depth understanding of the clinical and imaging presentations of metabolic and endocrine diseases of the axial and appendicular skeleton, including:
 - » Osteoporosis
 - » Hyperparathyroidism
 - » Renal osteodystrophy
 - » Amyloidosis
 - » Gaucher disease
 - » Storage diseases
 - » Osteogenesis imperfect
 - » Marfan's syndrome
 - » Paget disease
 - » Hypertrophic osteoarthropathy
 - » Sarcoidosis
 - » Tuberous sclerosis

- To have an in-depth understanding of the clinical and imaging presentations of congenital diseases of the axial and appendicular skeleton, including:
 - » Flatfoot and clubfoot
 - » Osteochondrodysplasia
 - » Failure of growth and development of cartilage and fibrous tissue
 - » Anomaly in density and modelling
 - » Dysostosis
 - » Chromosomal anomalies
- To have an in-depth understanding of the clinical and imaging presentations of bone and soft tissue tumours and tumour-like conditions of the axial and appendicular skeleton, including:
 - » Systematic assessment of a solitary lesion of bone and its categorization as aggressive or nonaggressive
 - » Appropriate differential diagnosis based on patient's age, lesion location and characteristics - boundaries, matrix, periosteal reaction, soft tissue extension
- To understand a systematic, safe and cost-effective radiologic work-up of bone lesions, including biopsy approach and compartmental anatomy
- To understand normal post-operative findings and complications of common orthopaedic procedures and hardware placement, including findings of loosening and infection of orthopaedic hardware
- To know the clinical and imaging presentations of skeletal and soft tissue injuries (including sports injuries, skeletal manifestations of child abuse), common congenital syndromes and clinically relevant developmental dysplasias (e.g. focal growth disturbances, DDH, coalitions, dysplasias, irritable hip, spinal deformity) in the paediatric age group
- To have a detailed knowledge of interventional musculoskeletal procedures, including interventions of the spine such as discography, nerve root injections, epidural injections, facet / SI joint injections, vertebroplasty, kyphoplasty
- To understand the role of nuclear medicine and densitometry techniques in the musculoskeletal system
- To have an in-depth understanding of radiotracers used in musculoskeletal applications
- To have an in-depth knowledge of MRI safety issues as they pertain to musculoskeletal imaging (including Gadolinium-related concerns such as nephrogenic systemic fibrosis / NSF)
- To understand the potential impact of technologic development and last results of research on musculoskeletal imaging practice
- To understand the concepts of Artificial intelligence (AI), Deep learning, Machine learning, Neural network and the potential applications on MSK

SKILLS

- To define skeletal age and to recognise appropriate / abnormal skeletal growth
- To recognise differences between normal variants and pathology
- To confidently differentiate stable and unstable traumatic injuries of the skeleton
- To recommend appropriate imaging (radiography, CT, MRI, ultrasound, nuclear medicine studies, hybrid imaging) of common and uncommon musculoskeletal conditions as subspecialty expert

- To perform / supervise and interpret all imaging techniques (radiography, CT, MRI, ultrasound, nuclear medicine studies, hybrid imaging) and procedures relevant to the investigation and management of musculoskeletal diseases to high standard
- To maintain a log of all procedures performed including complications
- To perform basic physical examinations of the musculoskeletal system prior to imaging
- To evaluate a standard two-view radiographic examination to respect all quality items
- To guide the technician in performing additional views, suggesting optimal patient's positioning
- To supervise the imaging quality of radiograms performed by technicians showing how to obtain good views also in challenging situations (e.g. in multitrauma patients)
- To perform ultrasound examination of the upper (i.e. shoulder, arm, elbow, forearm, wrist and hand) and lower (i.e. hip, thigh, knee, leg, ankle and foot) extremities and to diagnose the most common pathologic conditions in these areas
- To perform basic ultrasound examination of the neck, thoracic cage and abdominal wall
- To confidently plan and supervise a CT examination in musculoskeletal radiology and to tailor it to the individual situation with a dose as low as reasonably achievable
- To perform (and/or guide the technician in performing) post-processing of musculoskeletal CT examinations, with appropriate rendering and MPR and MIP reconstructions
- To confidently perform (and/or guide the technician in performing) a standard MRI examination of the upper and lower extremities, thoracic cage, abdominal wall, pelvis and neck (as pertinent to musculoskeletal radiology) respecting all quality items and tailor it to the individual patient situation in regard to spatial and contrast resolution and to the potential use of intravenous contrast medium administration
- To perform (and/or guide the technician in performing) post-processing of musculoskeletal MRI examinations, including temporal subtraction of dynamic contrast-enhanced studies, region-of-interest-based dynamic analyses and calculation of apparent diffusion coefficient from DWI acquisitions
- To perform (and/or guide the technician in performing) post-processing musculoskeletal hybrid imaging examinations, including image fusion
- To perform placement of needles into different joints using fluoroscopy or ultrasound as guidance without supervision
- To confidently perform and interpret an arthrogram (combined with fluoroscopy, CT or MRI) without supervision
- To manage potential complications (including post-procedural infection)
- To use sterile preparation techniques throughout all procedures in musculoskeletal interventions
- To safely plan and execute both small and large joint injections without supervision
- To choose the best biopsy system and the best technique for biopsy guidance for musculoskeletal indications, taking into account patient comfort and cost-effectiveness principles
- To manage common intra- and post-procedural complications in musculoskeletal interventions
- To accurately and safely perform ultrasound-guided / CT-guided procedures on joints and soft tissue
- To perform image-guided biopsies of bone and soft tissue masses
- To safely perform image-guided drainage procedures of abscesses, haematomas and serous collections in the musculoskeletal system

- To perform and present research-related work related to scientific questions and/or evidence-based improvement and quality work in the field of musculoskeletal radiology
- To critically review the literature and research articles in the field
- To conduct a research study and to evaluate and present the results in a scientific manner
- To understand the potential impact of technological development and learn how to translate results of research into clinical practice

COMPETENCES AND ATTITUDES

- To require minimal supervision from senior colleagues in the routine musculoskeletal imaging workflow
- To select the optimal imaging method for imaging disorders of the musculoskeletal system according to the clinical problem and justify the use of diagnostic imaging examinations and/or interventional procedures
- To choose the best-suited method to address specific clinical questions in musculoskeletal radiology according to current guidelines
- To communicate with the patient and to obtain informed consent prior to musculoskeletal imaging
- To describe and explain the nature of potentially complex radiological tests (including nuclear medicine and hybrid imaging) / procedures in musculoskeletal imaging to patients and, where necessary, clinical colleagues
- To choose optimal protocols for radiographic, CT, MRI and hybrid imaging examinations of the musculoskeletal system
- To create and apply protocols and standard operating procedures to reduce exposure doses for radiological examinations in musculoskeletal radiology
- To supervise and teach technical staff to ensure that appropriate images are obtained for all radiological methods in musculoskeletal radiology
- To judge the quality of imaging examinations in musculoskeletal radiology and to devise strategies to maintain high quality standards
- To link clinical presentations and radiological findings in musculoskeletal imaging with likely diagnosis or, at least, reasoned differential diagnoses
- To construct a concise, informative radiology report in musculoskeletal imaging with, where appropriate, recommendations for further radiological tests
- To confidently interpret and report radiographic, CT, MRI and hybrid imaging examinations of the musculoskeletal system
- To discuss radiological findings in orthopaedic medicine with referring physicians at peer level
- To confidently lead the radiological aspects of multidisciplinary team meetings in musculoskeletal imaging
- To be able to discuss both routine and more complex musculoskeletal imaging cases with radiology colleagues, referring clinicians and patients, also explaining the level of uncertainty of particular cases
- To appreciate and respect the roles and work of other non-medical personnel (including radiographers, nurses, support staff, secretaries etc.) in the musculoskeletal imaging unit and communicate with them in a professional manner

- To actively and positively interact with the other specialists of the multidisciplinary musculoskeletal team (such as orthopaedic surgeons, rheumatologists, physical therapists etc.), being an integrated member of the team in planning diagnostic studies, therapies and in outcome review
- To prioritise radiological workflow in musculoskeletal imaging as based on clinical urgency
- To identify urgent and/or unexpected findings in imaging examinations of the musculoskeletal system and to communicate these timely and properly
- To identify complex cases in musculoskeletal imaging, in which it is appropriate to obtain a second opinion for interpreting and reporting
- To retrieve current information on state-of-the art procedures in musculoskeletal imaging such as guidelines from national and international societies
- To continuously keep abreast of the key recent publications in the field of orthopaedic medicine, pathology and imaging
- To have audit and research skills in musculoskeletal imaging
- To present findings and lecture at meetings relevant to musculoskeletal imaging
- To teach musculoskeletal imaging
- To participate in discussions with other staff regarding operational challenges and potential system solutions regarding the workflow and other aspects of the musculoskeletal radiology service

B-III-9 NEURORADIOLOGY

Content provided by ESNR (European Society of Neuroradiology)

For Level III training in neuroradiology, it is recommended that the candidate should acquire basic knowledge in clinical neuroscience, such as neurology, neurosurgery or neuropathology.

KNOWLEDGE

- To have an in-depth knowledge of embryology, anatomy and physiology of the central and peripheral nervous systems
- To have an in-depth knowledge of embryology anatomy and physiology of the skull, skull base, extracranial head, spine and spinal cord
- To have the knowledge to confidently set up, perform and post-process perfusion studies, both with CT and MRI
- To have the knowledge to confidently set up, perform and post-process neuro-functional MRI studies
- To have the knowledge to confidently set up, perform and post-process diffusion and diffusion tensor imaging (DTI) MRI studies
- To have the knowledge to confidently set up, perform and post-process MR spectroscopy, both as a single-voxel and multi-voxel technique
- To have the knowledge to confidently set up, perform and post-process hybrid examinations (e.g. PET/CT, PET/MRI) in cognitive disorders, neuro-oncology, movement disorders, head and neck tumours)
- To know other imaging modalities like SPECT, PET in the brain, skull, skull base, extracranial head, spine, and peripheral nervous system and to understand their possible benefits and limitations
- To know and understand the medico-legal rules and regulations in regard to neuroradiology existing in the specific country the fellow is training
- To know and understand the regulations and individual protocols existing at the specific hospital the fellow is training
- To understand the development of protocols for phase I, phase II and phase III trials in neuroradiology
- To understand the most important statistical methods for analysing data in neuroradiology
- To have an in-depth understanding of radiotracers used in hybrid imaging in neuro-applications
- To have the knowledge of the pharmacological, pathophysiological, regulatory and legal aspects related to gadolinium-based contrast materials, especially with respect to allergic reactions, nephrogenic systemic fibrosis and gadolinium deposition

SKILLS

- To confidently and independently interpret and report radiographs, ultrasonographic examinations, CT studies and MRI examinations of the brain, skull, skull base, extracranial head, spine, spinal cord and peripheral nervous system

- To confidently and independently interpret and report on functional CT, functional MRI and hybrid imaging examinations of the brain, skull, skull base, extracranial head, spine and spinal cord and peripheral nervous system
- To confidently independently interpret and report on neurovascular and diagnostic angiographic examinations of the intra- and extracranial vessels
- To confidently plan a CT examination of the brain, skull, skull base, extracranial head, and spine and to tailor it to the individual situation, with a dose as low as reasonably achievable
- To confidently plan CT perfusion and MR perfusion studies of the brain and extracranial head including the volume and rate of application of contrast medium and the number of acquisitions
- To confidently plan and perform hybrid imaging techniques
- To confidently plan an MRI examination of the brain, skull, skull base, extracranial head, peripheral nervous system and spine / spinal cord and to tailor it to the individual situation in regard to the potential use of intravenous contrast medium and spatial resolution
- To confidently plan and perform advanced CT and MRI examinations including diffusion tensor imaging (DTI), functional MRI (fMRI) and proton MR spectroscopy (MRS)
- To be familiar with post-processing tasks of neuroradiological studies, including multiplanar reformations (MPR), maximum intensity projections (MIP), minimum intensity projections (MinIP), DTI, functional MRI and hybrid imaging
- To perform diagnostic neuroangiography
- To perform fluoroscopic or CT-guided biopsies and percutaneous interventional procedures
- To be familiar with quantitative imaging analysis, e.g. for white matter lesion quantification, cortical thickness mapping of gray matter, assessment of traumatic brain injury, etc.
- To perform and present research-related work related to scientific questions and/or evidence-based improvement and quality work in the field of neuroradiology
- To critically review the literature and research articles in the field
- To conduct a research study and to evaluate and present the results in a scientific manner
- To understand the potential impact of technological development and learn how to translate results of research into clinical practice

ADDITIONAL IN NEUROINTERVENTIONAL TRAINING

- To know potential risks and complications of the common procedures
- To be aware of the pharmacological actions of the agents used in analgesia and sedation and the necessary monitoring required to perform this safely
- To perform diagnostic neuroangiography
- To perform mechanical thrombectomy in patients with ischemic stroke
- To perform endovascular treatment of intracranial aneurysms
- To perform embolisation therapy of arteriovenous fistulas (AVF)
- To perform embolisation therapy of arteriovenous malformations (AVM)
- To perform stenting of intracranial arteries and supra-aortic vessels

- To perform spinal angiography
- To perform embolisation therapy of spinal AVM and AVF
- To perform spinal blood patch treatment
- To perform percutaneous interventional procedures of the extracranial head

ADDITIONAL IN INTERVENTIONAL SPINE TRAINING

- To perform disk, vertebral and facet interventional procedures included discography and biopsy
- To perform kyphoplasty and vertebroplasty
- To perform pain treatment procedures

ADDITIONAL IN NEUROPAEDIATRIC TRAINING

- To perform and report fetal MRI
- To perform and report ultrasonography, CT and MRI of the brain and spine in neonates and children

COMPETENCES AND ATTITUDES

- To require minimal supervision from senior colleagues in the routine neuroradiological workflow
- To select the optimal imaging method in neuroradiology according to the clinical problem and justify the use of diagnostic imaging examinations and/or interventional procedures
- To choose the best-suited method to address specific clinical questions in neuroradiology according to current guidelines
- To communicate with the patient and to obtain informed consent prior to neuroradiological examinations
- To describe and explain the nature of potentially complex neuroradiological tests / procedures to patients and, where necessary, clinical colleagues
- To choose optimal protocols for radiographic, CT, MRI and hybrid imaging examinations in neuroradiology
- To create and apply protocols and standard operating procedures to reduce exposure doses for neuroradiological examinations
- To supervise and teach technical staff to ensure that appropriate images are obtained for all neuroradiological methods
- To judge the quality of neuroradiological examinations and to devise strategies to maintain high quality standards
- To link clinical presentations and neuroradiological findings with likely diagnosis or, at least, reasoned differential diagnoses
- To construct a concise, informative neuroradiology report with, where appropriate, recommendations for further neuroradiological tests
- To confidently interpret and report radiographic CT, MRI and hybrid imaging examinations in neuroradiology
- To discuss neuroradiological findings with referring physicians at peer level
- To confidently lead the neuroradiological aspects of multidisciplinary team meetings

- To be able to discuss both routine and more complex neuroradiological cases with colleagues, referring clinicians and patients, also explaining the level of uncertainty of particular cases
- To have audit and research skills in neuroradiology
- To appreciate and respect the roles and work of other non-medical personnel (including radiographers, nurses, support staff, secretaries etc.) and communicate with them in a professional manner
- To actively and positively interact with the other specialists of the multidisciplinary team (such as neurologists, neurosurgeons, oncologists etc.), being an integrated member of the team in planning diagnostic studies, therapies and in outcome review
- To prioritise neuroradiological workflow as based on clinical urgency
- To identify urgent and/or unexpected findings in neuroradiological examinations to communicate these timely and properly
- To identify complex cases in neuroradiology, in which it is appropriate to obtain a second opinion for interpreting and reporting
- To retrieve current information on state-of-the-art procedures in neuroradiology such as guidelines from national and international societies
- To continuously keep abreast of the key recent publications in the field of neuroradiology
- To present findings and lecture at meetings relevant to neuroradiology
- To teach neuroradiology
- To participate in discussions with other staff regarding operational challenges and potential system solutions regarding the workflow and other aspects of the neuroradiology service

B-III-10 ONCOLOGIC IMAGING

Content provided by ESOI (European Society of Oncologic Imaging)

KNOWLEDGE

CANCER: BIOLOGY, ANATOMY, PRESENTATION & TREATMENT

- To describe the evolution of cancer and to understand the principles of angiogenesis, lymphangiogenesis and metastasis
- To describe the pathways of spread of cancer
- To have knowledge of atypical presentations and patterns of cancers
- To have knowledge of the principles of treatment including surgery, locoregional therapies e.g. radiofrequency ablation, chemotherapy, (systemic and targeted therapies; adjuvant and neoadjuvant) radiotherapy (conventional, brachytherapy, and stereotactic) and immunotherapy
- To describe the clinical management of cancers and the role of imaging within the clinical pathways

IMAGING TECHNIQUES

- To describe the different modalities employed in imaging cancer including X-ray, US, CT, MRI, SPECT, PET, PET/CT, PET/MRI
- To describe the role of interventional radiology for the treatment of patients with cancer
- To have an understanding of the strengths and limitations of different imaging methods in different clinical scenarios including diagnosis, biopsy site selection - staging, treatment planning, treatment response, surveillance and to have knowledge of the most appropriate imaging test
- To describe indications and contraindications for the various imaging examinations for diagnosis, staging, treatment response, surveillance
- To describe the most appropriate contrast agent or molecular tracer and its optimal use according to the imaging technique and the clinical problem
- To have an in-depth understanding of radiotracers used in hybrid imaging in oncology
- To understand the relative costs of the various imaging examinations
- To know the radiation burden and risks of different investigations

PRINCIPLES OF ADVANCED IMAGING TECHNIQUES AND CONTRAST AGENTS

- To describe techniques for post-processing images in view of obtaining reformat, MIP, MinIP, vessel analysis, 3D analysis, including endoluminal reconstructions, fusion images as well as acquisition and treatment of functional studies
- To understand the principles of advanced MRI techniques used in oncologic imaging including:
 - » Dynamic contrast-enhanced (DCE) MRI
 - » Diffusion-weighted imaging (DWI)
 - » Spectroscopy using ^1H , ^{31}P , ^{13}C ,
 - » Targeted contrast agents and fMRI (BOLD)
- To understand the principles of advanced CT techniques including dynamic contrast-enhanced CT (perfusion CT) and spectral imaging
- To understand the principles of contrast-enhanced ultrasound (CEUS)
- To describe the advanced imaging protocols and methods of image analysis and data processing used for the different advanced MRI, CT and US techniques
- To describe hybrid imaging protocols, methods of hybrid image analysis and data processing and possible pitfalls and limitations of this technique
- To describe the mechanism and use of the clinically most relevant PET radiotracers
- To understand the challenges of implementing advanced imaging techniques in research and clinical practice
- To understand the challenges of advanced imaging biomarker development in clinical trials: generalisability, qualification standardisation, QA, QC

SCREENING, STAGING, TREATMENT PLANNING, RESPONSE ASSESSMENT & SURVEILLANCE

- To understand the principles of screening, the organisation of screening using breast, lung and colorectal cancer as core examples and to have awareness of international guidelines
- To appreciate the main advantages and drawbacks of a screening programme
- To describe the principles of staging of cancers and to have knowledge of the staging systems in clinical use
- To have an appreciation of common imaging 'false positives' and 'false negatives' at staging, and the role of different imaging techniques for lesion characterisation
- To know the international guidelines for staging common cancer types
- To describe the various roles of imaging in treatment planning, e.g. surgery, radiotherapy
- To have an understanding of the principles of response assessment and an appreciation for the advantages and limitations of the different response criteria, e.g. RECIST, combined size and enhancement criteria and PET criteria e.g. PERCIST, including knowledge of the following terms: baseline examination, nadir, tumour response, tumour progression, stable disease, target lesion, non-target lesions, new lesions, pseudoprogression
- To understand the concept of clinical trials: main endpoints for evaluation of treatments like response rate, disease control rate, time to progression, disease-free and progression-free survival, and best overall response
- To be aware of the current therapeutics undergoing evaluation and in the developmental pipeline and the mechanism of action of these agents

- To describe the patterns of recurrence in different cancer types and to have core knowledge of the role of imaging in assessing suspected disease recurrence, and the advantages and limitations of different techniques
- To describe the advantages and disadvantages of different imaging techniques in surveillance in different cancers
- To have knowledge about treatment-related diseases

INTERVENTIONAL RADIOLOGY

- To describe the basic principles of safe interventional technique, the anatomy relevant to the procedure and the recognised complications of the procedures
- To be familiar with the wide range of interventional techniques used in oncological radiology, including radioembolisation
- To describe the common procedures including for percutaneous fine needle aspiration, biopsy or drainage using image-guidance
- To know the potential risks and complications of the common procedures
- To be aware of the pharmacological actions of the agents used in analgesia and sedation and the necessary monitoring required to perform this safely
- To describe the processes and actions required in intermediate life support and management of anaphylaxis

RESEARCH

- To describe research techniques that may be applied to imaging research in cancer

SKILLS

- To justify, protocol, conduct and supervise oncological imaging examinations to a high standard
- To confidently tailor imaging examinations appropriately to the clinical question in oncology
- To confidently interpret all images relevant in the diagnosis, staging, assessment of response and detection of recurrent disease of the common cancers
- To develop resources to be able to diagnose, stage, assess response of unusual tumour types using all imaging modalities
- To accurately assess response to treatment according to recognised objective response criteria
- To advise on the appropriate diagnostic imaging and follow-up protocols for different tumour types
- To plan effective imaging pathways for the common cancers
- To confidently discuss the appropriate imaging strategies within a multidisciplinary tumour board
- To communicate effectively with patients and professional colleagues
- To provide clinicians with optimised images which may aid surgical management or treatment planning including the role of imaging in radiotherapy planning and treatment
- To have detailed knowledge of basic US, CT, MRI, nuclear medicine and PET/CT (PET/MR) techniques, findings and pitfalls in diagnosis in those cancers frequently referred for imaging
- To understand the indications for functional and molecular imaging techniques in oncologic imaging

- To competently work with US-, CT- and MRI-guided interventions and, where appropriate, fluoroscopic imaging
- To competently undertake the following procedures:
 - » US-guided biopsy of masses and lymph nodes
 - » CT-guided biopsy of masses (retroperitoneal, pelvic side-wall, thoracic and lymph nodes)
 - » MRI-guided biopsy of masses and lymph nodes
 - » drainage of collections
- To perform and present research-related work related to scientific questions and/or evidence-based improvement and quality work in the field of oncologic imaging
- To critically review the literature and research articles in the field
- To conduct a research study and to evaluate and present the results in a scientific manner
- To understand the potential impact of technological development and learn how to translate results of research into clinical practice

COMPETENCES AND ATTITUDES

- To conduct good clinical care: to be able to justify, protocol, conduct and supervise oncological imaging examinations to a high standard and to tailor examinations appropriately to the clinical question
- To maintain good medical practice: to be able to discuss current medical practice with colleagues and patients, and show competences by appraisal
- To work in partnership with patients: to be able to explain diagnostic and therapeutic radiology procedures effectively, to take informed consent and be flexible in approaching patients, taking into account different learning styles and expectations of patients
- To demonstrate good team working skills: to understand the value of working in a multidisciplinary team, to demonstrate good communication with professional colleagues e.g. informing clinicians of unexpected findings that will alter management
- To assure and improve the quality of care: to be able to describe an effective clinical governance approach and to participate in clinical governance processes, e.g. clinical audit, guidelines development.
- To require minimal supervision from senior colleagues in the routine urogenital radiology workflow
- To select the optimal imaging method in oncologic imaging according to the clinical problem and justify the use of diagnostic imaging examinations and/or interventional procedures
- To communicate with the patient and to obtain informed consent prior to oncologic imaging examinations
- To describe and explain the nature of potentially complex oncologic radiological tests / procedures to patients and, where necessary, clinical colleagues
- To choose optimal protocols for radiographic, US, CT, MRI and hybrid imaging examinations in oncologic radiology
- To create and apply protocols and standard operating procedures to reduce exposure doses for oncologic imaging examinations
- To supervise and teach technical staff to ensure that appropriate images are obtained for all oncologic imaging methods

- To judge the quality of oncologic imaging examinations and to devise strategies to maintain high quality standards
- To link clinical presentations and oncologic imaging findings with likely diagnosis or, at least, reasoned differential diagnoses
- To construct a concise, informative and possibly structured report in oncologic radiology with appropriate recommendations for further radiological tests
- To confidently interpret and report radiograph US, CT, MRI and hybrid imaging examinations in oncologic radiology
- To discuss findings in oncologic radiology with referring physicians at peer level
- To confidently lead the oncologic imaging aspects of multidisciplinary team meetings
- To be able to discuss both routine and more complex oncologic imaging cases with colleagues, referring clinicians and patients, also explaining the level of uncertainty of particular cases
- To appreciate and respect the roles and work of other non-medical personnel (including radiographers, nurses, support staff, secretaries etc.) in the oncologic imaging unit and communicate with them in a professional manner
- To actively and positively interact with the other specialists of the multidisciplinary oncologic team, being an integrated member of the team in planning diagnostic studies, therapies and in outcome review
- To prioritise oncologic radiological workflow as based on clinical urgency
- To identify urgent and/or unexpected findings in oncologic imaging examinations to communicate these timely and properly
- To identify complex cases in oncologic radiology, in which it is appropriate to obtain a second opinion for interpreting and reporting
- To retrieve current information on state-of-the art procedures in oncologic radiology such as guidelines from national and international societies
- To continuously keep abreast of the key recent publications in the field of oncologic radiology
- To have audit and research skills in oncologic radiology
- To present findings and lecture at meetings relevant to oncologic imaging
- To teach oncologic radiology
- To participate in discussions with other staff regarding operational challenges and potential system solutions regarding the workflow and other aspects of the oncologic radiology service

B-III-11

PAEDIATRIC RADIOLOGY

Content provided by ESPR (European Society of Paediatric Radiology)

KNOWLEDGE

- To have an in-depth understanding of changes in anatomy and in physiology during growth from foetal life to adolescence
- To know normal variants in childhood that may mimic disease
- To have an in-depth understanding of embryology as applied to paediatric diseases
- To have an in-depth understanding of the various stages of embryonic and foetal development and their respective appearance on antenatal US and foetal MRI
- To understand and describe the principles guiding the construction of a child-friendly environment
- To have an in-depth knowledge of the ALARA principle and dose considerations and their application in paediatric patients
- To list imaging guideline algorithms specific to children
- To have an in-depth knowledge of indications and contraindications for contrast media for fluoroscopy, ultrasound, CT and MRI within the paediatric population including neonates
- To know the principles of nuclear medicine and to appreciate the relationship and comparison with conventional radiology, CT and MRI
- To describe principles and applications of hybrid imaging techniques (SPECT/CT, PET/CT, PET/MRI) in infants, children and adolescents
- To be familiar with physiological clearance, dosage and radiation exposure of radiopharmaceuticals and PET tracers
- To understand indications and the range of treatment strategies for common interventional radiological procedures in foetuses, neonates, infants and children
- To describe the standard procedures in emergency situations, including resuscitation techniques in children
- To ensure adequate monitoring of patients during sedation or interventional procedures

BRAIN AND SPINE

- To understand the imaging features of malformations of cortical development, including focal cortical dysplasia, polymicrogyria, heterotopia (subependymal, focal subcortical, laminar), lissencephaly / pachygyria, (hemi) megalencephaly, microlissencephaly and schizencephaly and their contribution in the identification of tubulinopathies
- To know the imaging features of agenesis and dysgenesis of the corpus callosum and of holoprosencephaly (lobar, semilobar, alobar)
- To understand the imaging features of hindbrain malformations, including the Chiari malformations, the Dandy-Walker spectrum, Blake's pouch cyst and vermian malformations (including Joubert syndrome)

- To know the imaging features, causes, grading, prognosis and clinical features of white matter injury of prematurity / periventricular leukomalacia
- To understand the imaging features, causes grading, prognosis and clinical features of subependymal and intraventricular haemorrhage in premature infants
- To understand the imaging features of hypoxic ischemic encephalopathy of the mature infant after acute asphyxia or prolonged partial hypoxia
- To understand the imaging features, causes and clinical features of hydrocephalus in infants, children and adolescents
- To understand the imaging features, causes and clinical features of benign enlargement of subarachnoid spaces in infants
- To understand the clinical and imaging findings of craniosynostosis and their significance
- To have an in-depth knowledge of the imaging features and clinical features of elevated intracranial pressure in infants, children and adolescents
- To have an in-depth knowledge of the imaging features and clinical features of different brain tumours in infants, children and adolescents, including the molecular classification, the principle of radiological staging, treatment and monitoring of follow-up
- To have an in-depth knowledge of the imaging features and clinical features of head trauma in infants, children and adolescents
- To understand the imaging features, clinical features and implications of non-accidental trauma in infants, children and adolescents and to be able to recommend and supervise further extracranial imaging according to recommendations
- To have an in-depth knowledge of the imaging features and clinical features of intracranial infections (including antenatal infections, e.g. TORCH group) in infants, children and adolescents
- To know the imaging features of multiparametric studies including hybrid imaging with SPECT and PET-tracers in brain and spine tumours and cerebral palsy
- To have an in-depth knowledge of the imaging features and clinical features of inflammatory diseases of the CNS
- To have an in-depth knowledge of the imaging features and clinical features of metabolic and developmental diseases of the white matter
- To know the imaging features, causes and clinical features of intracranial ischaemia / stroke / arterial and venous malformations in infants, children and adolescents
- To have an in-depth knowledge of the imaging features, changes with age and clinical features of pituitary disease in infants, children and adolescents
- To know the imaging features and clinical features of spinal malformations including spina bifida aperta, spina bifida occulta, meningomyelocele, dermal sinus, split cord malformations and tethered cord with clear knowledge of what is considered clinically significant vs. non-clinically significant findings
- To have an in-depth knowledge of the imaging features and clinical features of acquired diseases of the spinal cord in children

HEAD AND NECK

- To have a deep understanding of the anatomy and embryology of the head and neck region in children
- To understand the imaging features of congenital disorders leading to deafness (e.g. cochlear aplasia / hypoplasia, Mondini malformation, large endolymphatic sac anomaly (LESA) / large vestibular aqueduct syndrome (LVAS), incomplete partition type I and II)
- To know the imaging features and clinical features of congenital lesions of the orbit, including coloboma
- To know the imaging features and clinical features of typical tumours of the orbit in children including dermoid and epidermoid cysts, cavernous haemangioma, lymphatic malformations, rhabdomyosarcoma and retinoblastoma, including the principle of radiological staging, treatment and monitoring of follow-up
- To understand the imaging features and clinical features of congenital and acquired lesions of the paranasal sinuses and salivary glands including choanal atresia, frontoethmoidal encephalocele, tumours, inflammatory lesions, infections and their complications
- To know the imaging features of nuclear imaging including SPECT and hybrid imaging (SPECT/CT, PET/CT, and PET/MRI) in malignant solid tumours of the head and neck region
- To know the imaging features and clinical features of congenital lesions of the oral cavity, oropharynx and neck, including dermoid and epidermoid cysts, accessory salivary tissue, lymphatic malformation and lingual thyroid gland
- To have an in-depth knowledge of tumours of the head and neck region in infants, children and adolescents, including tumours of the orbit, the skull base, the salivary glands, the tonsils and related principle of radiological staging, treatment and monitoring of follow-up
- To have an in-depth knowledge of the imaging features and clinical features of traumatic lesions of the head and neck region in infants, children and adolescents
- To have a deep understanding of the infections of the head and neck region, their imaging appearances, complications and different treatment options
- To describe the imaging features and clinical features of thymus ectopia and cysts
- To know the imaging features and clinical features of vascular lesions including vascular and lymphatic malformations of the head and neck region
- To describe the imaging features and clinical features of fibromatosis colli

CHEST

- To understand the imaging features of normal thymus, its variants and acquired diseases including tumours and Langerhans Cell histiocytosis in infants, children and adolescents
- To describe the imaging features of congenital abnormalities of bronchial tree and chest (bronchopulmonary foregut malformation spectrum: congenital pulmonary airway malformations (including distinctive features of pulmonary sequestration, congenital pulmonary airway malformation, lobar emphysema, bronchial atresia, pulmonary venolobar ("Scimitar") syndrome) in infants, children and adolescents, including knowledge of their antenatal imaging findings
- To understand the imaging features and complications of neonatal lung anomalies in premature and term infants and neonates, especially with radiography and ultrasonography

- To know appropriate and abnormal appearances and positions of lines and tubes in neonates, infants, and children
- To understand imaging features of ChILD (childhood interstitial lung disease) in neonates, infants, children and adolescents
- To have an in-depth understanding of the imaging features, complications and implications for management of foreign body aspiration and ingestion in infants, children and adolescents
- To have an in-depth understanding of the imaging features and complications of bronchiolitis in infants, children and adolescents
- To have an in-depth understanding of the imaging features of cystic fibrosis in infants, children and adolescents
- To have an in-depth understanding of the imaging features and significance of acute and chronic or recurrent lower respiratory tract infection in infants, children and adolescents
- To have an in-depth understanding of the imaging features and significance of opportunistic infections and lung toxicities in infants, children and adolescents
- To understand the imaging features, significance and causes of chest wall lesions, pleural effusions and pleural-based abnormalities in infants, children and adolescents
- To know the clinical, radiographic and CT imaging features of chest trauma including the imaging features of pneumothorax and other air-leaks in infants, children and adolescents
- To have an in-depth understanding of the imaging, etiologic and follow-up features of infiltrative diseases of the lung in infants, children and adolescents
- To know the imaging features of mediastinal masses (germ cell tumour, cystic mediastinal masses, lymphadenopathies, lymphoma, neurogenic tumours) in infants, children and adolescents, including the principle of radiological staging, treatment and monitoring of follow-up
- To have an in-depth understanding of the imaging features and implications of metastatic diseases to the lung in infants, children and adolescents
- To know the imaging features of hybrid imaging (SPECT/CT, PET/CT, and PET/MRI) in malignant solid tumours of the chest and metastatic disease of the lung
- To know the antenatal and postnatal imaging features of congenital diaphragmatic hernia, diaphragm palsy and eventration in infants, children and adolescents
- To have an in-depth knowledge of breast disease in the paediatric age and adolescent girls, including prioritization of imaging exams and knowledge of the main pathological entities

CARDIOVASCULAR

- To be familiar with typical imaging appearances of cardiac anomalies on chest radiographs
- To have a basic understanding of paediatric cardiac MRI and CT, their differences and main indications
- To understand the imaging features and clinical features of the main congenital malformations of cardiovascular system including aortic arch abnormalities, vascular rings and slings, tetralogy of Fallot and transposition of the great arteries in infants, children and adolescents
- To know the imaging features, causes and clinical features of arterial hypertension in infants, children and adolescents

- To describe the imaging features, causes and clinical features of inflammatory (i.e. vasculitic / rheumatological related) and infectious disorders of the cardiovascular system in infants, children and adolescents
- To have an in-depth knowledge of the imaging features and clinical features of traumatic lesions of the cardiovascular system in infants, children and adolescents
- To have a basic understanding of the surgical techniques used in children, the imaging appearances of changes / amendments to the vascular anatomy and potential complications for major cardiovascular malformations (e.g. Blalock-Taussig shunt, Fontan procedure, Norwood surgeries)
- To know the main imaging features of cardiac and pericardial tumours
- To know the main pathologies of the coronary arteries in children
- To have a basic knowledge of the imaging appearance of cardiomyopathies in children
- To have an in-depth knowledge of the imaging features and clinical features of vascular malformations and vascular tumours in infants, children and adolescents, including its classification, ultrasonographic and MR presentations

DIGESTIVE TRACT

- To have an in-depth knowledge of antenatal ultrasound and foetal MRI features of congenital malformations of the digestive tract including protocols for postnatal follow-up
- To know the clinical and imaging features of oesophageal atresia and tracheo-oesophageal fistulae in neonates
- To know the clinical and imaging features of necrotizing enterocolitis including complications like pneumoperitoneum in neonates
- To know the clinical and imaging features of anorectal malformations in neonates
- To know the clinical and imaging features of hypertrophic pyloric stenosis in neonates and infants
- To understand the clinical and imaging features of high and low gastrointestinal obstruction in neonates
- To know the clinical and imaging features and complications of Hirschsprung disease in neonates, infants, children and adolescents
- To know the clinical and imaging features of gastro-oesophageal reflux in infants, children and adolescents
- To know the clinical and imaging features of intestinal malrotation and volvulus in infants, children and adolescents
- To have an in-depth knowledge of the types, imaging features and clinical features of primary and secondary intestinal intussusception in infants, children and adolescents
- To have an in-depth knowledge of the clinical and imaging features of appendicitis and other entities affecting the appendix in infants, children and adolescents
- To understand the clinical and imaging features of peritonitis in neonates, infants, children and adolescents
- To understand the clinical and imaging features of inguinal hernia in infants, children and adolescents
- To know the clinical and imaging features of inflammatory bowel diseases and the respective complications in infants, children and adolescents
- To know the imaging features and clinical features of miscellaneous non-inflammatory bowel diseases and the respective complications in infants, children and adolescents, including Haemolytic uremic syndrome, typhlitis, purpura, malabsorption

- To know the indications for imaging, clinical and imaging features of blunt abdominal trauma in infants, children and adolescents with relevant multimodality imaging protocols
- To have an in-depth understanding of the clinical, imaging features and possible complications of digestive tract foreign bodies in infants, children and adolescents
- To know the US, CT, MRI and MRCP imaging findings, clinical and laboratory features of disorders of the hepatobiliary system in infants, children and adolescents (including jaundice in infants, biliary atresia, choledochal cyst, benign liver tumours)
- To have an in-depth knowledge of the imaging features of different aetiologies of acute or chronic liver diseases, the principle of imaging staging and monitoring of follow-up in infants, children and adolescents
- To have an in-depth knowledge of indications and technique of liver biopsy in infants, children and adolescents
- To know the clinical and imaging features of disorders of portal circulation in infants, children and adolescents
- To have an in-depth knowledge of the imaging features of liver tumours, including features in contrast-enhanced ultrasonography, the principle of radiological staging, treatment and follow-up in cases of malignancies in infants, children and adolescents
- To understand normal appearances and complications in the post-transplant liver
- To know the clinical and imaging features of disorders of the pancreas in infants, children and adolescents
- To know the clinical and imaging features of disorders of the spleen in infants, children and adolescents
- To know the imaging features of hybrid imaging (SPECT/CT, PET/CT and PET/MRI) in malignant solid tumours of the digestive tract

GENITO-URINARY TRACT

- To have an in-depth knowledge of the imaging features of antenatal aspects of malformations of the urinary tract including protocols and methodology for follow-up
- To list main CAKUT (Congenital Anomalies of Kidney and Urinary tract) such as horseshoe kidney, ectopia, fusion, duplications, anomalies of vesicoureteral junction and associated nephropathies
- To have an in-depth understanding of the clinical and imaging features of urinary tract infection in infants, children and adolescents
- To have an in-depth understanding of the imaging features of the different grades of vesico-ureteral reflux and urethral anomalies on all modalities (fluoroscopy, scintigraphy, contrast-enhanced Ultrasonography)
- To know the clinical and imaging features of dilatation of the urinary tract in infants, children and adolescents
- To understand the imaging features and clinical features of cystic diseases of the kidneys and associated syndromes in infants, children and adolescents
- To understand the imaging features and clinical features of urolithiasis and nephrocalcinosis and underlying predisposing factors in infants, children and adolescents
- To know the clinical features and imaging features of oncologic disorders of the urogenital system and retroperitoneum in infants, children and adolescents, including neuroblastoma, Wilms' tumours, other renal tumours, Burkitt's lymphoma, rhabdomyosarcoma and other bladder tumours including differential diagnosis including the principles of radiological staging, treatment and follow-up

- To know the indications and technique of percutaneous renal or retroperitoneal tumour biopsy
- To describe the clinical features and imaging features of common disorders of the adrenal glands in infants, children and adolescents
- To understand the clinical features and imaging features of sexual development disorders in neonates and infants, and to classify these accordingly
- To understand the clinical features and imaging features of pubertal development disorders in infants and adolescents
- To understand the clinical features and imaging features of common gynaecological disorders (ovarian torsion, malformations, cysts and tumours)
- To have an in-depth knowledge of the different aetiologies of ovarian tumours in girls, including the principles of radiological staging, treatment and follow-up
- To know the clinical features and imaging features of common disorders of the testis and scrotum in boys (including testicular torsion, testicular appendix torsion, hydroceles, epididymitis, varicoceles, purpura, idiopathic scrotal edema and testicular tumours)
- To know the imaging features of hybrid imaging (SPECT/CT, PET/CT and PET/MRI) in malignant solid tumours of the genito-urinary tract

MUSCULOSKELETAL

- To have an in-depth knowledge of the antenatal investigation strategy of suspected bone malformations and constitutional bone disease
- To have an in-depth knowledge of the clinical features and imaging features of fractures (accidental and non-accidental) in neonates, infants, children and adolescents including diagnosis and monitoring of healing and complications
- To understand the imaging recommendations and medico-legal aspects of non-accidental injury
- To know the clinical features and imaging features of accidental trauma and polytrauma in infants, children and adolescents
- To describe the clinical features and imaging features of common bone dysplasia (achondroplasia, osteogenesis imperfecta, congenital metabolic disorders) in children and adolescents
- To understand the clinical features and imaging features of infiltrative bone marrow diseases in infants, children and adolescents, including complications and principles of monitoring (e.g. transcranial Doppler, iron overload imaging) of common haemoglobinopathies (including sickle cell disease and thalassaemia)
- To have an in-depth knowledge of the clinical features, imaging features, complications and principles of metabolic bone diseases including those of rickets
- To have an in-depth knowledge of the clinical features, imaging features, complications and principles of monitoring of bone tumours in children and adolescents, including the principle of radiological staging, treatment and follow-up in cases of malignancies
- To know the imaging features of hybrid imaging (SPECT/CT, PET/CT and PET/MRI) in bone and soft tissue diseases in children

- To know the imaging features, differential diagnosis and clinical significance of joint disorders in children and adolescents
- To understand the clinical features, imaging features and complications of osteomyelitis and septic arthritis in neonates, children and adolescents
- To know the clinical features, imaging features, complications and principles of monitoring of Chronic recurrent multifocal osteomyelitis / Chronic Non-bacterial Osteomyelitis (CRMO/CNO) in children and adolescents
- To understand the clinical features, imaging features, complications and principles of monitoring of juvenile idiopathic arthritis (JIA) and haemophilia in children and adolescents, including the principle of radiological scoring, treatment and follow-up
- To have an in-depth knowledge of the imaging features and clinical features of congenital disorders of the spine, including scoliosis (congenital and idiopathic), and dysraphism in infants, children and adolescents
- To have an in-depth knowledge of the clinical, imaging features, complications and treatment options of developmental dysplasia of the hips in neonates, infants, children and adolescents
- To understand the clinical features, imaging features, complications and principles of monitoring of Legg-Calvé-Perthes disease in children
- To understand the clinical features, imaging features and complications of slipped capital femoral epiphysis in children
- To know the clinical features and imaging features of congenital disorders of the ankle and foot, including congenital tarsal coalition and talipes equinovarus
- To understand the clinical features and imaging features of osteochondrosis and juvenile disc disease, including Scheuermann's disease, in children and adolescents
- To understand the differences regarding clinical and imaging findings between acute and chronic sports injuries in the growing skeleton

KNOWLEDGE OF ENTITIES AND CONDITIONS AFFECTING MULTIPLE SYSTEMS

- To understand the clinical features, diagnostic criteria, neuro-imaging features and extracranial manifestations of neurofibromatosis type I and II, including principles of radiological staging, treatment and monitoring of follow-up
- To understand the neuro-imaging features, extracranial manifestations, diagnostic criteria and clinical features of tuberous sclerosis, including principles of radiological staging, treatment and monitoring of follow-up
- To understand the clinical features, diagnostic criteria, neuro-imaging features and extracranial manifestations of Sturge-Weber disease
- To understand the clinical features, diagnostic criteria, neuro-imaging features and extracranial manifestations of von Hippel-Lindau disease, including principles of radiological staging, treatment and monitoring of follow-up
- To have a basic knowledge of the imaging features of less common neurocutaneous syndromes
- To understand the clinical features and imaging features of haematological disorders in children and adolescents

- To know the clinical features and imaging features of Langerhans cell histiocytosis, including principles of radiological staging, treatment and monitoring of follow-up
- To understand the imaging features, clinical features and complications of HIV infections and other immunosuppression disorders in neonates, children and adolescents
- To understand normal and abnormal post-transplant findings in children and adolescents
- To appreciate post-operative, post-chemotherapy and post-radiotherapy changes and their significance in children and adolescents
- To understand the applications and limitations of postmortem imaging in children
- To understand indications for and advantages of intervention instead of surgery in neonates, infants, children and adolescents

SKILLS

- To understand the role and limitations of antenatal US and MRI for the diagnosis of congenital anomalies and the contribution of prenatal imaging to counselling
- To perform ultrasound examinations in neonates, infants, children and adolescents and to appreciate the technical difference between portable and departmental ultrasound machines
- To choose the most suitable contrast material (oral, per rectum, intracavitary, intravenous) and its optimal use according to the imaging technique, the clinical problem and the age in paediatric radiology
- To perform ultrasound of the brain and spine in infants
- To perform Doppler sonography of the vessels, including intracranial vessels, in neonates, infants, children and adolescents
- To perform ultrasound of the hip and other joints in neonates and infants especially for hip dysplasia and acquired joint diseases
- To perform ultrasound of the neck, chest, abdomen and pelvis in neonates, infants, children and adolescents
- To perform contrast-enhanced Ultrasonography with intravascular and intracavitary use of contrast in children, when indicated
- To apply techniques to reduce radiation exposure during fluoroscopy
- To perform voiding cystourethrography in neonates, infants, children and adolescents
- To perform contrast media studies of the gastrointestinal tract in neonates, infants, children and adolescents including a tube esophagogram for H-type tracheoesophageal fistula
- To confidently perform a reduction procedure in ileo-colic intussusception
- To confidently plan a CT examination in neonates, infants, children and adolescents and to tailor it to the individual situation and age with radiation doses as low as reasonably achievable
- To confidently plan an MRI examination in fetuses, neonates, infants, children and adolescents and to tailor it to the individual situation and age of the patient with regard to the potential use of intravenous contrast medium and spatial resolution
- To appreciate how to plan a hybrid examination (SPECT/CT, PET/CT, PET/MRI) at least the radiological part in neonates, infants, children and adolescents and to tailor it to the individual situation and age of the patient with regard to the potential use of intravenous contrast medium and spatial resolution

- To confidently perform proper post-processing tasks of examinations in paediatric radiology, including multiplanar reformations (MPR), maximum intensity projections (MIP), minimum intensity projections (MinIP) and fusion images in hybrid techniques
- To know the principles of nuclear imaging, especially DMSA, MAG3 renogram, MIBG, bone scintigraphy and to appreciate the relationship and comparison / complementary or additional role with conventional CT and MRI
- To have basic knowledge of basic treatment options, to know definite applications of interventional radiology in neonates, infants, children and adolescents and be able to recommend referral to a specialist paediatric interventional radiologist
- To know the standard procedure in emergency situations, including resuscitation techniques in children
- To understand and plan the need and use of sedation and general anaesthesia in children and ensure adequate monitoring of patients during sedation or interventional procedures
- To perform and present evidence-based research related to daily practice, scientific questions and quality improvement in the field of paediatric radiology
- To critically review the scientific literature in the field
- To conduct a research study and to evaluate and present the results in a scientific manner
- To understand the potential impact of technological development including artificial intelligence (AI) and learn how to translate results of research into paediatric radiology clinical practice

COMPETENCES AND ATTITUDES

- To require minimal supervision from senior colleagues in the routine paediatric imaging work-flow
- To select the optimal imaging method for imaging in paediatric radiology according to the clinical problem and justify the use of diagnostic imaging examinations and/or interventional procedures
- To choose the best-suited method to address specific clinical questions in paediatric radiology according to current guidelines
- To communicate with the patient and the parents / caretakers and to obtain proper informed consent where applicable
- To describe and explain the nature of potentially complex radiological tests / procedures including hybrid examinations (SPECT/CT, PET/CT, PET/MRI) in paediatric imaging to patients and, where necessary, clinical colleagues
- To choose optimal protocols for sonographic, radiographic, CT, MRI, nuclear medicine and hybrid imaging (SPECT/CT, PET/CT, PET/MRI in centres where radiologists also perform nuclear medicine and hybrid imaging) examinations in infants, children and adolescents
- To create and apply protocols and standard operating procedures to reduce exposure doses for radiological examinations and hybrid imaging examinations (SPECT/CT, PET/CT, PET/MRI) in infants, children and adolescents
- To supervise and teach technical staff to ensure that appropriate images are obtained for all radiological methods in paediatric radiology

- To judge the quality of imaging examinations in paediatric radiology and to devise strategies to maintain high quality standards
- To link clinical presentations and radiological and hybrid findings in paediatric imaging with likely diagnoses / reasoned differential diagnoses
- To construct a concise, informative radiology report with, where appropriate, recommendations for further radiological tests
- To confidently interpret and report radiographic examinations, fluoroscopy, US, CT, MRI (including hybrid examinations, SPECT/CT, PET/CT, PET/MRI) in foetuses, neonates, infants, children and adolescents
- To confidently lead the radiological aspects of multidisciplinary team meetings in paediatric imaging
- To be able to discuss both routine and more complex paediatric imaging cases with radiology colleagues, referring clinicians, patients and parents / caretakers, also explaining the level of uncertainty of particular cases
- To appreciate and respect the roles and work of other non-medical personnel (including sonographers, radiographers, nurses, support staff, secretaries etc.) in the paediatric imaging unit and communicate with them in a professional manner
- To actively and positively interact with the other specialists of the multidisciplinary paediatric team, being an integrated member of the team in planning diagnostic studies, therapies and in outcome review
- To prioritize radiological workflows in paediatric imaging, based on clinical urgency
- To identify urgent and/or unexpected findings in paediatric imaging examinations and to communicate and document these in a timely and appropriate manner
- To identify complex cases in paediatric imaging, in which it is appropriate to obtain a second opinion for interpreting and reporting
- To retrieve current information on state-of-the art procedures in paediatric imaging such as guidelines from national and international societies
- To continuously keep abreast of the key recent publications in the field of paediatric medicine, surgery, pathology and radiology
- To have audit and research skills in paediatric imaging
- To present findings and lecture at meetings relevant to paediatric imaging including meetings discussing adverse events and discrepancies
- To teach paediatric imaging to radiology trainees, other physicians, allied health professionals and students
- To participate in discussions with other staff regarding operational challenges and potential system solutions regarding the workflows and other aspects of the paediatric radiology service

B-III-12 UROGENITAL RADIOLOGY

Content provided by ESUR (European Society of Urogenital Radiology)

KNOWLEDGE

KIDNEYS, ADRENALS, URETERS

- To have an in-depth understanding of the renal physiology and the pharmacokinetics of contrast agents
- To describe the dynamics of intravascular contrast media and functional studies of the renal compartments
- To have an in-depth knowledge of the imaging features and clinical features of tumours of the adrenal glands
- To differentiate benign and malignant masses of the adrenal glands in the adult and in the paediatric population
- To describe the imaging features, pathways of spread and staging of malignant tumours of the adrenal gland
- To describe the imaging features of incidentalomas of the adrenal glands
- To understand the management of patients presenting with hormonally active adrenal tumours
- To know the imaging features and clinical features of adrenal insufficiency
- To know the imaging features and clinical features of adrenogenital syndrome
- To know the imaging features and clinical features of inflammatory diseases of the adrenal glands
- To describe the clinical and imaging features of congenital disorders of the urinary system
- To know the imaging features of congenital anomalies of the kidneys and upper and lower urinary tract
- To have an in-depth knowledge of the clinical and imaging features of urinary tract obstruction
- To have an in-depth knowledge of the clinical and imaging features of acute and chronic urinary obstruction, including differential diagnosis and pseudo-obstruction
- To understand the clinical and imaging features of vesicoureteral reflux and refluxing nephropathy
- To describe the interventional and surgical management of patients presenting with urinary tract obstruction
- To have an in-depth knowledge of the clinical and imaging features of clinical and imaging features of urolithiasis
- To understand the composition of urinary tract calculi and their radiological correlation
- To understand current imaging strategies in patients presenting with renal colic
- To describe the interventional and surgical management of patients presenting with renal calculus (ESWL, endoscopic, percutaneous, stone dissolution)
- To have an in-depth knowledge of the clinical and imaging features of clinical and imaging features of renal inflammatory diseases
- To describe the common causes of renal infections in adults and in children
- To be aware of rare infections, including tuberculosis, brucellosis, xanthogranulomatous pyelonephritis, malakoplakia, fungal infections and echinococcosis
- To understand the presentation of urogenital diseases in the immunocompromised (neutropenia and HIV/AIDS) patient, including:
 - » Infectious diseases: bacterial, fungal, viral pneumocystis, tuberculosis, atypical mycobacteria autoimmune related diseases
 - » Malignancy and lymphoproliferative diseases: Kaposi sarcoma, lymphoma and other primary tumours
- To have an in-depth knowledge of the clinical and imaging features of neoplasms of the kidney and ureters
- To understand the current algorithms for staging renal malignant tumour
- To describe the clinical and imaging features of renal neoplasms in children
- To understand the clinical and imaging features of renal vascular disorders

- To understand the clinical and imaging features of renal infarction
- To describe the clinical and imaging features of renal vascular malformations
- To understand the concept of renal vascular hypertension
- To describe the clinical and imaging features of venous embolism and occlusion
- To understand the clinical and imaging features of nephropathies
- To understand the clinical and imaging features after renal transplantation
- To be familiar with the assessment of living donors
- To understand the diagnosis and management of complications after renal transplantation
- To understand the clinical and imaging features of the post-operative kidney and urinary tract
- To have an in-depth knowledge of the expected findings and complications after surgery / interventional procedures of the kidneys
- To understand the added value of hybrid imaging compared to other imaging modalities in kidneys, adrenals and ureters

RETROPERITONEUM

- To have an in-depth knowledge of the clinical and imaging features of diseases of the retroperitoneum
- To describe the diagnosis and management of retroperitoneal fibrosis
- To describe the diagnosis and management of retroperitoneal haemorrhage
- To describe the diagnosis and management of primary and secondary retroperitoneal tumours
- To understand the added value of hybrid imaging compared to other imaging modalities in the retroperitoneum

BLADDER AND URETHRA

- To be familiar with the concept of urachal anomalies
- To have an in-depth knowledge of the clinical and imaging features of hernias, bladder and urethral diverticula
- To have an in-depth knowledge of the clinical and imaging features of inflammatory disorders of the bladder
- To have an in-depth knowledge of the clinical and imaging features of bladder tumours
- To understand the diagnosis of urinary incontinence and functional disorders
- To know the clinical and imaging features of diseases of the urethra
- To be familiar with the management of patients with urogenital trauma
- To understand the added value of hybrid imaging compared to other imaging modalities in bladder and urethra

FEMALE GENITAL AND OBSTETRIC IMAGING

- To understand the clinical and imaging features of congenital malformations of the uterus and vagina (Müllerian abnormalities), in association with urinary abnormalities and complications
- To have an in-depth knowledge of the clinical and imaging features of tumours of the uterus
- To have an in-depth knowledge of benign tumours of the endometrium and myometrium
- To be familiar with the management of uterine leiomyomas
- To understand the subtypes, imaging, pathways of spread and staging of endometrial cancer
- To be familiar with the malignant neoplasm of corpus uteri, including sarcoma, neuroendocrine tumours, lymphoma and metastases
- To have an in-depth understanding of the subtypes, imaging, pathways of spread and staging of cervical cancer
- To be familiar with gestational trophoblastic disease
- To understand the clinical and imaging features of tumours of the vulva, vagina and perineum
- To be familiar with benign diseases of the cervix

- To be familiar with benign diseases of the vulva and vagina
- To be familiar with benign diseases of the perineum
- To know the subtypes, imaging, pathways of spread and staging of malignant tumours of the vulva and vagina
- To have an in-depth understanding of the clinical and imaging features of tumours of the ovaries and adnexa
- To be familiar with the management of ovarian cysts in pre-and postmenopausal age
- To understand the clinical and imaging features of polycystic ovarian disease
- To be familiar with the clinical and imaging features of paraovarian tumours
- To understand the clinical and imaging features of benign ovarian tumours
- To know the subtypes, imaging, pathways of spread and staging of malignant ovarian tumours
- To be familiar with the clinical and imaging features of ovarian metastases
- To understand the clinical and imaging features of peritoneal carcinomatosis
- To know the staging strategies and staging of ovarian cancers
- To be familiar with benign and malignant tumours of the Fallopian tubes
- To know the clinical and imaging features of endometriosis
- To understand the clinical and imaging features of pelvic inflammatory and its complications
- To have an in-depth understanding of the diagnostic management of acute pelvic pain
- To be familiar with the diagnostic management of chronic pelvic pain syndromes
- To understand the diagnostic and therapeutic strategies in female infertility
- To understand the clinical and imaging features in hereditary gynecological cancers
- To understand the clinical and imaging features in recurrence of cancer of the female genital organs
- To understand the clinical and imaging features of the post-operative uterus
- To know the clinical and imaging features of radiotherapy-associated findings in the female pelvis (acute and chronic, normal and complications)
- To have an in-depth understanding of the clinical and imaging features in pregnancy-associated disorders
- To have an in-depth understanding of uterine disorders associated with pregnancy
- To have an in-depth understanding of uterine disorders during delivery
- To have an in-depth understanding of complications in the post-partum period (uterine and not uterine, e.g. ovarian vein thrombosis, haematoma with superinfection)
- To know disorders of the ovaries associated with pregnancy and the post-partum period
- To be familiar with image-guided therapeutic approaches in severe post-partum bleeding
- To have an in-depth understanding of the differential diagnoses in pregnant patients with symptoms of an acute abdomen (maternal and obstetrical)
- To be familiar with the principles and quantitative parameters of MR pelvimetry
- To be familiar with the principles of foetal MRI
- To understand the added value of hybrid imaging compared to other imaging modalities in the female reproductive system

MALE REPRODUCTIVE SYSTEM

- To know the clinical and imaging features of congenital disorders of the male genital organs (e.g. ectopic testis, cryptorchism, hypospadias)
- To have an in-depth understanding of the clinical and imaging features of tumours of the prostate
- To know the clinical and imaging features of prostatic cysts
- To have an in-depth understanding of the clinical and imaging features of benign prostatic hyperplasia
- To have an in-depth understanding of the subtypes, imaging, pathways of spread and staging of cancers of the prostate

- To report MRI of the prostate according to international standards (PI-RADS V.2.1)
- To differentiate other malignant diseases of the prostate
- To be familiar with multimodality-guided prostate biopsies
- To understand the clinical and imaging features in inflammatory disorders of the prostate
- To know the clinical and imaging features of acute and chronic prostatitis
- To know the clinical and imaging features of abscesses of the prostate
- To have an in-depth knowledge of the clinical and imaging features of benign and malignant tumours of the scrotum
- To know the subtypes, imaging patterns, pathways of spread and staging of malignant neoplasm of the testis
- To be familiar with the subtypes, imaging, pathways of spread and staging of malignant extratesticular tumours
- To perform multiparametric US of the acute scrotum and obtain differential diagnosis of common and uncommon causes of acute scrotal pain
- To understand clinical and imaging features of inflammatory disorders of the testis
- To know the clinical and imaging features of diseases of vascular disorders of the scrotum
- To know the clinical and imaging features of testicular torsion
- To know the clinical and imaging features of infarction and vasculitis of the scrotum
- To know the clinical and imaging features of benign tumours of the penis
- To understand the subtypes, imaging, pathways of spread and staging of malignant neoplasms of the penis
- To be familiar with the clinical and imaging features of Peyronie's disease
- To understand the strategies for imaging males with erectile dysfunction
- To be familiar with the diagnosis and management of priapism
- To understand complications of penile prostheses
- To know the clinical and imaging features of recurrence in cancer of the male genital organs
- To understand the imaging strategies for diagnosis of prostate cancer recurrence
- To know the strategies for imaging follow-up of patients treated for testicular cancer
- To understand clinical and imaging strategies in male infertility
- To understand the added value of hybrid imaging compared to other imaging modalities in the male reproductive system

PELVIC FLOOR

- To understand clinical and imaging features of disorders of the pelvic floor
- To know treatment strategies and post-operative imaging of pelvic floor disorders
- To understand the clinical and imaging features of pelvic prolapse
- To know the clinical and imaging features of female and male urinary incontinence
- To know the clinical and imaging features of faecal incontinence
- To understand the added value of hybrid imaging compared to other imaging modalities in tumours of the pelvic floor

GENERAL

- To know the ESUR guidelines
- To recognise the contraindications of the imaging modalities / techniques used in urogenital radiology
- To have an appreciation of the role of hybrid imaging in staging and follow-up of GU malignancies
- To have an in-depth understanding of radiotracers used in hybrid imaging for GU malignancies

SKILLS

- To perform and supervise, interpret and report all imaging techniques and procedures relevant to the investigation and management of genitourinary diseases to high standard. The use of quantitative data for diagnosis and reporting is encouraged
- To choose the most appropriate imaging examination according to the clinical problem in urological, female and male genital radiology and in obstetric radiology
- To select the most suitable contrast material and/or radiotracer and its optimal use according to the patient, the imaging technique and the clinical problem in urogenital radiology
- To confidently perform a transabdominal and/or transvaginal ultrasound in urogenital disorders
- To confidently perform a transabdominal and/or transvaginal ultrasound in pregnant patients
- To report / perform hysterosalpingography, if performed at the site
- To confidently plan and supervise a CT examination in urogenital radiology and to tailor it to the individual situation with a radiation dose and contrast medium dose as low as reasonably achievable
- To confidently plan and supervise an MRI examination in urogenital radiology and to tailor it to the individual situation of the patient in regard to the potential use of intravenous contrast medium and spatial resolution
- To plan and supervise a hybrid imaging examination in urogenital radiology and to tailor it to the individual situation of the patient
- To plan and supervise a pelvimetric MR examination in the pregnant patient
- To plan and supervise dynamic MR examinations in patients with pelvic floor disorders
- To perform defecography in patients with pelvic floor disorders
- To accurately and safely perform image-guided biopsies of masses related to the adrenals, the kidneys, the urogenital tract and the retroperitoneum
- To safely perform image-guided drainage procedures of collections related to the adrenals, the kidneys, the urogenital tract and the retroperitoneum
- To have a basic understanding of the role of interventional radiology in managing diseases of the GU tract
- To observe and/or perform percutaneous nephrostomy
- To follow the ESUR guidelines
- To choose the most suitable contrast medium and its optimal use according to the individual patient, the clinical problem and the imaging technique
- To identify and take preventive action in patients at risk of contrast media nephrotoxicity
- To perform and present research-related work related to scientific questions and/or evidence-based improvement and quality work in the field of urogenital radiology
- To critically review the literature and research articles in the field
- To conduct a research study and to evaluate and present the results in a scientific manner
- To understand the potential impact of technological development and learn how to translate results of research into clinical practice

COMPETENCES AND ATTITUDES

- To require minimal supervision from senior colleagues in the routine urogenital radiology workflow
- To select the optimal imaging method in urogenital radiology according to the clinical problem and justify the use of diagnostic imaging examinations and/or interventional procedures
- To choose the best-suited method to address specific clinical questions in urogenital radiology according to current guidelines

- To communicate with the patient and to obtain informed consent prior to urogenital imaging examinations
- To describe and explain the nature of potentially complex urogenital radiological tests / procedures to patients and, where necessary, clinical colleagues
- To choose optimal protocols for radiographic, CT, MRI and hybrid imaging examinations in urogenital radiology
- To create and apply protocols and standard operating procedures to reduce exposure doses for urogenital imaging examinations
- To supervise and teach technical staff to ensure that appropriate images are obtained for all urogenital imaging methods
- To judge the quality of urogenital imaging examinations and to devise strategies to maintain high quality standards
- To link clinical presentations and urogenital imaging findings with likely diagnosis or, at least, reasoned differential diagnoses
- To construct a concise, informative report in urogenital radiology with, where appropriate, recommendations for further radiological tests
- To confidently interpret and report radiographic CT, MRI and hybrid imaging examinations in urogenital radiology
- To discuss findings in urogenital radiology with referring physicians at peer level
- To confidently lead the urogenital imaging aspects of multidisciplinary team meetings
- To be able to discuss both routine and more complex urogenital imaging cases with colleagues, referring clinicians and patients, also explaining the level of uncertainty of particular cases
- To appreciate and respect the roles and work of other non-medical personnel (including radiographers, nurses, support staff, secretaries etc.) in the urogenital imaging unit and communicate with them in a professional manner
- To actively and positively interact with the other specialists of the multidisciplinary team (such as urologists, nephrologists or gynaecologists), being an integrated member of the team in planning diagnostic studies, therapies and in outcome review
- To prioritise urogenital radiological workflow as based on clinical urgency
- To identify urgent and/or unexpected findings in urogenital imaging examinations to communicate these timely and properly
- To identify complex cases in urogenital radiology, in which it is appropriate to obtain a second opinion for interpreting and reporting
- To retrieve current information on state-of-the art procedures in urogenital radiology such as guidelines from national and international societies
- To continuously keep abreast of the key recent publications in the field of urogenital radiology
- To have audit and research skills in urogenital radiology
- To present findings and lecture at meetings relevant to urogenital radiology
- To teach urogenital radiology
- To participate in discussions with other staff regarding operational challenges and potential system solutions regarding the workflow and other aspects of the urogenital radiology service

B-III-13 MEDICAL IMAGING INFORMATICS

Content provided by the ESR eHealth and Informatics Subcommittee in collaboration with EuSoMI (European Society of Medical Imaging Informatics)

INTRODUCTION

Medical Imaging Informatics today is necessary to all clinical radiology subspecialisations, modern radiology would not exist without Imaging Informatics. Levels I and II of the ETC in Imaging Informatics provide the trainee with the competences to understand and make use of Imaging Informatics at the user level. Level III of this curriculum intends to enable the trainee to actively manage Imaging Informatics in all clinical radiology domains. The understanding is that there is need for a bridge between clinical radiology and the more technical disciplines (physics and informatics). Radiologists with an in-depth knowledge of Imaging Informatics will be enabled to translate clinical needs into Imaging Informatics applications, typically within an interdisciplinary team of radiologists, informaticians and physicists. Knowledge, skills, competences and attitudes obtained are applicable in any radiology specialisation.

KNOWLEDGE

KNOWLEDGE OF RADIOLOGY WORKSTATIONS, NETWORKS, RIS, PACS AND EPR

- To understand basic networking principles and configuration parameters
- To understand the standards of file exchange and to have knowledge of the recording and digitizing technology use for image integration
- To know about the required interconnections between imaging-related digital systems and systems outside the imaging department
- To know about enterprise storage strategies
- To understand the composition of a radiological workstation and to understand the technical basics of radiological diagnostic screens (monitors), such as resolution, contrast, brightness and SNR (signal to noise ratio)
- To know about the purpose and means of performing quality controls of radiological workstations, including screens
- To understand the implementation of plug-in tools within the workstations
- To have advanced knowledge of different Medical Information Systems used in the imaging department, such as PACS, RIS and the EPR. To understand the relationship between EPR, RIS and PACS
- To understand electronic order Entry Systems
- To know about data integration in the hospital. To be aware of the PACS needs of other medical specialties
- To understand the principles of Enterprise PACS, including the issues related to archiving non-radiological images and linking those to clinical events and other patient data

KNOWLEDGE OF STANDARDS AND CODES

- To have an overview of the content of the DICOM and HL7 standard
- To have advanced knowledge of IHE, especially in the radiology domain. To know how to find and check for relevant IHE profiles
- To have knowledge of and understand coding systems relevant for radiology, such as RadLex, SnoMed, SNOMED-CT, LOINC and ICD-9/10
- To know about the digital Imaging Adopting Model (DIAM) framework, including clinical audits and decision support systems

KNOWLEDGE OF RADIOLOGICAL SOFTWARE APPLICATIONS

- To know about the general principles and the more specific applications of image post-processing techniques related to the following issues:
 - » Visualisation: to know about different techniques used to create and display 2D and 3D images, such as MIP, MPR, SSD
 - » Segmentation: to know about different image segmentation techniques in image processing (region-based vs. pixel-based, edge-based and model-based segmentation)
 - » Registration: to know the main techniques and results of image registration
 - » Reliability of automated processes: to understand the value and risks of automated image postprocessing and analysis tools
- To have knowledge about 3D printing techniques and their applications. To know about the steps involved in acquiring and preparing imaging data for 3D printing
- To understand the principles of using mobile devices in a healthcare environment, for sharing of medical data, including the involved issues related to patient privacy, safety and legal requirements
- To know how to use tools and procedure to assist radiologists, technicians and referring physicians with continuous quality improvement and dose management (for example PACS-integrated feedback and monitoring tools)
- To understand the principles of Structured Reporting (SR):
 - » To understand and have knowledge of the different types of structured reporting
 - » To have knowledge of the IHE-approved Management of Radiology Report Templates (MRRT) standard used for SR
 - » To have knowledge of the coding systems / mapping procedures that can be applied to SR, such as RadLex lexicon / ontology
 - » To have a knowledge of common data elements (CDE)
- To understand the role of image sharing on social media both for education of radiologists / other physicians as well as patients, and the privacy parameters surrounding this type of content
- To have knowledge about Computerized Physician Order Entry Systems (CPOE)
- To know how to implement image distribution using portable media
- To have knowledge of cross-enterprise document sharing systems such as cross-enterprise document sharing (XDS) and cross-enterprise document sharing for imaging (XDS-I)
- Understand image sharing approaches that do not require physical media, especially those that can be patient-driven (some overlap with XDS/XDS-I above)
- To know about teleradiology and its different applications and purposes (intramural vs. extramural, national vs. international, primary vs. secondary readings, second opinions)

- To know how to use business intelligence software to evaluate performance of radiology services
- To know how to use business intelligence software to communicate referral pattern data with referring physicians
- To have knowledge of Clinical Decision Support Systems (CDS) used for radiological purposes
- To know about the existing software for CAD (Computer Aided Diagnosis)
- To know about CAD applications for different imaging modalities (such as CT, MRI)
- To know about emerging technologies such as Artificial Intelligence classifiers for the provision of detection, diagnosis and other radiological purposes
- To know how to assess the performance of CAD and AI tools and critically appraise their applicability
- To know about the research, development and clinical integration of radiomics and imaging biomarkers
- To know the specific needs and possibilities of PACS, RIS and quantitative imaging for participating in clinical trials
- To understand the organizational structure and financial structure of the hospital and healthcare environment
- To know and understand the role of the DPO (Data Protection Officer)
- To know about the regulations and guidelines involved in teleradiology, both on a national and international (European) level
- To know about the requirements for de-identification to adhere to the rules and regulations when obtaining imaging data for research or teaching
- To know about de-identification, anonymization, pseudonimization and re-identification and the involved DICOM Supplement 142
- To know how to help create and use real-time electronic dashboard technology and its use to improve radiology workflows
- To have a basic understanding of similarities and differences between HIPAA in the US and GDPR in the EU

SKILLS

- To be able to use the Digital Imaging Adoption Model (DIAM) for evaluating the digital status of the department and hospital
- To be able to participate actively in the management of the Imaging Informatics of the radiology department and hospital
- To be able to assess the presence of policies adhering to the existing regulations and directives applicable to Imaging Informatics
- To be able to evaluate existing policies regarding management of digital data
- To be able to recommend process improvements, to construct policies and procedures
- To be able to implement the existing regulations concerning digital data into the workflow and protocols (procedures) for both patient care and research
- To be able to develop, implement, monitor and regulate policies and procedures, and establish accountability
- To be able to develop and implement standard protocols and guidelines for the use of advanced visualization applications
- To be able to have an active participating role in the planning of the digital investment plan of an imaging department

- To be able setup and participate in a PACS procurement:
 - » To analyse the financial implications of purchasing a PACS
 - » To list the key elements that must be considered in preparing a department for PACS
 - » To discuss the objectives and elements of a formal RFP document
 - » To interpret, evaluate and compare vendor proposals
 - » To list the standard components of a contract (pricing, implementation support, training, service, functionality, acceptance criteria, financing options)
 - » To negotiate contracts with vendors
- To evaluate, implement, support and manage the applications and/or interfaces necessary for interpretations of medical and radiological images
- To evaluate the requirements for seamless interfacing of EPR / RIS / PACS / other health informatics systems and to identify what IHE profiles must be available
- To describe the functions that the technologists and radiologists would use for image management
- To establish work processes and procedures for importing images into and exporting images from the PACS
- To be able to apply and use digital radiation exposure monitoring systems
- To be able to implement and apply Clinical Decision Support Systems (CDS) linked to the EPR and related to electronic ordering systems

COMPETENCES AND ATTITUDES

- To be able to actively participate in the selection trajectory of Medical Imaging Informatics applications such as PACS, EPR and Artificial Intelligence applications
- To be able to set up and maintain a quality management program related to Imaging Informatics, including all modalities used for medical imaging
- To be able to combine this knowledge and skills with the clinical needs at the imaging department and hospital, in order to give proper advice regarding the purchase requirements for new or replacement of Imaging Informatics applications and installations
- To be able to communicate relevant information related to medical imaging and Imaging Informatics among technologists, radiologists, clinicians and other users such as patients, on a hospital-wide basis
- To be able to communicate and discuss relevant issues regarding Imaging Informatics with the hospital administration team
- To be able to assess the Digital Imaging Adoption Model (DIAM) and use the information obtained from that analysis as a basis for further strategy development and investment planning, with the intention to upscale the digital level of the radiology department
- To be able to evaluate the adoption of IHE profiles and IHE-accepted standards in the radiology department and to control and promote the adherence to IHE profiles
- To be able to contribute to the creation and application of hospital-wide policies related to the appropriate management of digital data
- To fulfil a leadership role in Imaging Informatics in a radiology department
- To be able to motivate and educate radiologists in the usage and value of imaging biomarkers, and to guide the clinical implementation of these tools

- To be able to organize training and education related to Imaging Informatics, related to the implementation of new software applications and upgrades of existing applications
- To be able to guide radiologists in using image data for Deep Learning techniques and related research
- To be able to guide radiologists in implementing the usage of extracted quantitative data to enhance the value of radiological services and to improve patient care
- To be able to actively participate in setting up an IT disaster recovery plan
- To be able to execute and manage an IT disaster recovery plan

WWW.MYESR.ORG/TRAININGCURRICULUM

EUROPEAN TRAINING CURRICULUM FOR SUBSPECIALISATION IN RADIOLOGY